

## Long Pulsed Nd: YAG Laser Treatment for Hair Removal in Healthy Subject

Siti Maria Juwaini<sup>1\*</sup>, Ahmad Zailani Sukri<sup>2</sup>, Isma Liza Mohd Isa<sup>3</sup>

---



<sup>1</sup>Anggun Mediklinik,  
53330 Kuala Lumpur,  
Malaysia

<sup>2</sup>Department of  
Reconstructive & Plastic  
Surgery, Hospital Kuala  
Lumpur, 50586 Kuala  
Lumpur, Malaysia

<sup>3</sup>Department of Anatomy,  
Faculty of Medicine,  
UKM, 50300 Kuala  
Lumpur, Malaysia

### Abstract

Laser hair removal is a common aesthetic treatment that is safe and effective. Pulses of laser light facilitate the destruction of hair follicles, thus removing hair temporarily and permanently. Here, we reported a case of laser hair removal in a healthy male for aesthetic concern. Our patient was a 33-year-old man of Asian origin, presenting Fitzpatrick facial skin type IV with coarse facial hairs of the moustache. We successfully removed 80% of facial hairs of the moustache on the cutaneous upper lip in the patient using 1064 nm Nd:YAG laser treatment in combination with the cooling system over 12 sessions with a four-week interval. His facial condition was excellent without hair re-growth evidence with the absence of terminal hairs and had no adverse skin effect over 12-month laser treatment. In conclusion, Nd:YAG laser treatment provides an effective treatment for the persistent reduction of unwanted hair growth.

### Keywords:

Laser hair removal, Nd:YAG laser, Asian skin, facial hair

*Address of corresponding author:*  
*Anggun Mediklinik, 53330 Kuala*  
*Lumpur, Malaysia*

*Email:*

*anggunmediklinik@gmail.com*

While hair loss is a typical cosmetic issue among men, unsightly hair growth on body regions from the face, chin, underarm, back, leg, and other parts is a common aesthetic concern among males as their desire for neat looking grows. Hair removal procedures include shaving, tweezing, waxing, depilation, laser, and electrolysis procedure. Nevertheless, laser treatment is a favourable option due to its procedure that is less painful and can provide permanent hair removal in the large surface area (Bhat et al., 2020). To date, laser hair removal is now available in various methods, including the alexandrite (755 nm), diode (800–1000 nm), ruby laser (694 nm), and intense pulsed light (550–1200 nm) as well as long-pulsed neodymium yttrium-aluminum-garnet (Nd:YAG) (1064 nm) laser (Naik, 2021). Specifically, Asian skin is prone to pigmentary; therefore, the choice of laser and operator's technique are important factors for the success of laser hair removal without adverse effects. Here, we presented a case report of laser hair removal in Asian skin of a healthy male using 1064 nm Nd:YAG laser treatment.

### Case presentation

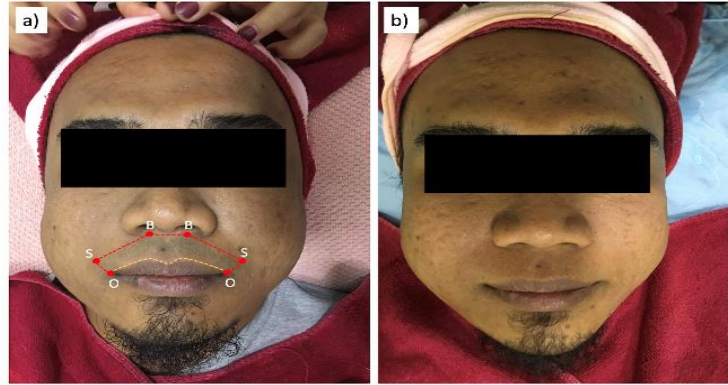
A 33-year-old healthy gentleman who was a salesman in Singapore came to our clinic presenting with a Fitzpatrick facial skin type IV without a tan, had an aesthetic concern to remove unwanted facial hairs on the moustache area for neat looking. He was vitally stable. He had not shown clinical signs indicating hormonal disorder and was not on medications. He never had a history of skin eruptions because of laser treatments. Following medical consultation, he underwent a laser hair removal on the moustache of the cutaneous upper lip region using a long-pulsed 1064 nm Nd:YAG laser device to obtain a high-performance hair

removal via the GentleMax Pro System (GPro System) over 12-course of treatments at a four-week interval from February 2019 until February 2020.

Pre-treatment, the patient had shaved the moustache to expose the hair follicle area of the cutaneous upper lip (**Fig. 1a**). Specifically, the anatomical landmarks of the upper line of the moustache were marked in red line as the superior outer line of the moustache (S) continues with the horizontal line between the alar base (A). The hairless moustache region was between the philtrum and columella. The moustache showed a bow-shaped convexity in the middle of the nostril. The lower line of the moustache was marked in a yellow line as it continues on the upper vermilion border to the level of oral commissure (O). The upper and lower line of the moustache continues symmetrically on the opposite side (Durgun et al., 2021). Post-treatment, we observed a significant hair removal of approximately more than 80% with the absence of terminal hairs of a moustache on the cutaneous upper lip region (**Fig. 1b**) after 12 sessions at four-week-interval of the 1064 nm Nd:YAG laser treatments combined with the cooling system of cryogen.

### Management and outcome

The parameters of the laser procedure were consistent over the 12-month study as outlined in Table 1, including 12 mm of spot size, pulse duration of 10 ms, 30 J/cm<sup>3</sup> in fluence at 1 Hz frequency. For the outcome, we observed on the percentage growth of terminal hairs. We have seen approximately 80% reduction of terminal hairs of the moustache in our patient following laser treatment using 1064 nm Nd:YAG laser over 12 sessions with four weeks intervals. Laser treatment is an aesthetic procedure for



**Fig. 1** The photographs of the anterior view of the patient's face. Anatomical landmarks of moustache region for hair removal before the laser treatment (a) and the absence of terminal hairs in the moustache area post-treatment of 1064 nm Nd:YAG laser treatment after 12 sessions over 12 months (b).

hair removal that uses light amplification by stimulated emission of radiation based on photothermolysis, in which energy provided at a particular wavelength is absorbed by the hair structure in a time that is less than or equal to the thermal relaxation time. In particular, the 1064 nm Nd:YAG laser provides cutting-edge laser technology that can specifically tailor for dark and coarse hair without damaging the surrounding skin. The laser with a 1064 nm wavelength passes through the skin deeply, where the laser light pulses facilitate the destruction of hair follicles in the dermis of the skin (Naik, 2021). It is suggested that targeting follicles in the early anagen phase of hair development is more receptive to laser

treatment due to the melanin is present in anagen hairs (Bhat et al., 2020). Herein, we recommended that the patient shave the moustache, leaving a small amount of hair inside the follicles before undergoing laser treatment for a better outcome of hair removal. In addition, the 1064 nm laser is safe for Fitzpatrick facial skin type IV due to the unique feature of epidermal melanin to poorly absorb light at this wavelength. The laser treatment is commonly combined with an additional cooling system such as cryogen to protect the epidermis layer of skin (Lim & Regina, 2011). Thus, our patient had shown no adverse effect following the 1064 nm Nd:YAG laser treatment.

**Table 1.** The setting of parameters in GentleMax Pro System prior to the laser procedure.

Parameters	1064 nm Nd:YAG laser + Cryogen (1,1,1,2 tetrafluoroethene)
Spot size (mm)	12
Pulse duration (ms)	10
Fluence (J/cm <sup>3</sup> )	30
Frequency (Hz)	1

## Discussion

The patient had shown the absence of terminal hairs of moustache in the cutaneous upper lip region following 1064 nm Nd:YAG laser treatment in one year. Our observation suggests that laser treatment is an effective procedure for

removing unwanted hair and preventing persistent hair re-growth in a healthy subject.

## Acknowledgements

We acknowledge our patient for permission to publish his case in this report.

## References

1. Bhat, Y. J., Bashir, S., Nabi, N., & Hassan, I. (2020). Laser Treatment in Hirsutism: An Update. *Dermatology Practical and Conceptual*, 10(2), 2–9. <https://doi.org/10.5826/dpc.1002a48>
2. Durgun, U., Ergün, S. S., Gayretli, Ö., Kelahmetoğlu, O., & Çamli, M. F. (2021). Anatomical Landmarks of the Beard Region. *Dermatologic Surgery*, 47(11). <https://doi.org/10.1097/dss.000000000000319>
3. Lim, S.-P., & Regina. (2011). Laser Hair Removal in the Asian Skin. In *Textbook of Laser and Light Dermatology in the Asian Skin* (pp. 69–81). [https://doi.org/10.1142/9789814338875\\_0007](https://doi.org/10.1142/9789814338875_0007)
4. Naik, P. P. (2021). Laser Hair Removal - Mechanisms and Complications. *Clinical Practice*, 18, 1566–1573.