

# Clinical, Dermoscopy and Histopathological findings of Exogenous Ochronosis: A Case Series

Maria Isabel Mendoza Belizario<sup>1\*</sup>, Julius Garcia Gatmaitan<sup>2</sup>, Johannes Flores Dayrit<sup>3</sup>

---



<sup>1</sup>Belizario Dermatology  
Clinic

<sup>2</sup>Gatmaitan Medical and Skin  
Center, Skines Aesthetic and  
Laser Center

<sup>3</sup>De La Salle Medical and  
Health Sciences Institute,  
Research Institute for  
Tropical Medicine

## Abstract

Hydroquinone is the gold standard of treatment for disorders of hyperpigmentation. However, complications such as Exogenous Ochronosis has become widespread due to its prolonged use. Clinical differentiation from other disorders of hyperpigmentation is difficult hence, correlation of dermoscopy and histopathology is warranted. Findings of blue-gray amorphous structures and hypopigmented areas of atrophy (confetti-like areas of depigmentation) in dermoscopy correlated with crescentic or “banana shaped” ochre-colored pigments and solar elastosis consistent with the diagnosis of Exogenous Ochronosis. The use of dermoscopy as a non-invasive tool is essential in distinguishing Exogenous Ochronosis from other disorders of hyperpigmentation. This aids in planning therapeutic options and improve patient outcomes.

**Keywords:** Exogenous Ochronosis, Dermoscopy, Hydroquinone, Histopathology

*Address of corresponding  
author:*

*Belizario Dermatology Clinic,  
Philippines*

*Email:*

*mariaisabelizario@gmail.com*

*Received: April 18, 2023*

*Revision received: June 14,  
2023*

*Accepted after revision: June  
21, 2023*

*www.japa-edu.org*

The Asian cosmetic market for whitening is growing rapidly and its demand increasing, due to aesthetic and cultural desires [1]. Its vast availability online and claims of great results have encouraged people to purchase and use these products without medical supervision [2]. Therefore, many complications are now being observed due to its misuse.

Hydroquinone remains to be the gold standard for conditions of hyperpigmentation [3]. Its unregulated presence over the counter has made its complications more visible. One of its dreaded complications is Exogenous Ochronosis (EO). Exogenous Ochronosis has first been defined by Findlay et al<sup>4</sup> with its association with using topical hydroquinone in 1975. It is a paradoxical hyperpigmentation that appears as gray-brown or blue-black macules and caviar-like papules on photo-exposed areas and osseous surfaces with contact to the chemical [5, 6]. It is cosmetically disfiguring and thus causes psychological turmoil among patients. Due to its clinical similarity to other pigmentary disorders, it may be difficult to differentiate one from the other. Hence, its correlation with dermoscopy and histopathology is warranted to

clinch proper diagnosis and improve patient outcomes and expectations.

### Case Report

Ten (10) cases of exogenous ochronosis were seen at the Research Institute for Tropical Medicine Manila, Philippines from March 2007- August 2019 with a male to female ratio of 1:9. Average age of patients was 53 years old. None of the patients presented with signs of endogenous ochronosis such as arthralgia, dark colored urine, hyperpigmentation of the sclerae, thickening of the pinnae nor dark cerumen.

All 10 patients used hydroquinone 2% solutions without sun protection for a mean duration of 5.3 years (Table 1). Clinically, the most common features observed were, confetti-like depigmentation (Figure 1a) in 80% of cases, caviar-like papules (Figure 1b) and visible telangiectasias (Figure 1c) in 40% of patients. All patients exhibited lesions on the malar area. Meanwhile 60% of patients showed lesions on the nasal area and 40% on the perioral area. Other patients showed lesions on the chin, upper eyelid, forehead, anterior chest and lateral eyebrows with decreasing frequency (Table 2).

Table 1: Demographic Data

Patient	Sex	Age in years	Duration of Hydroquinone 2% use
1	F	59	2 years
2	F	48	1 year
3	F	52	1 year
4	F	50	nil
5	F	50	10 years
6	F	56	5 years
7	F	49	8 years
8	F	53	6 years
9	M	60	10 years
10	F	55	5 years

Table 2: Area of distribution

Area of Distribution	Frequency
Malar	100%
Nasal	60%
Perioral area	40%
Chin	30%
Upper eyelid	20%
Forehead	20%
Anterior Chest	10%
Lateral eyebrows	10%

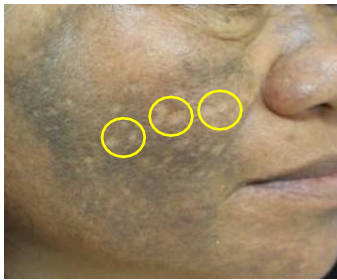

Figure 1a Confetti-like Depigmentation

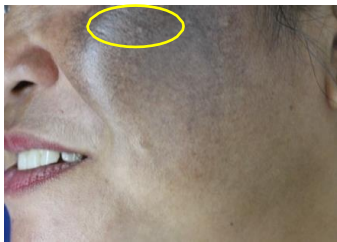

Figure 1b Caviar-like papules

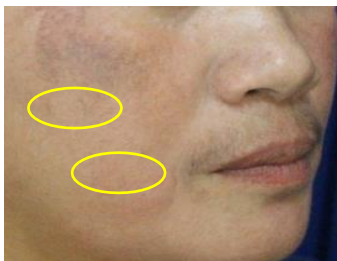


Figure 1c Visible Telangiectasias

Dermoscopy of all patients showed blue gray and black dots, annular and arcuate structures, reddish to dark -brown curvilinear structures, obliteration of follicular openings and telangiectasias. While only 80% of patients showed confetti-like depigmentation (Figure 2a and 2b). Histopathology findings showed the pathognomonic finding of ochre-colored bodies in various shapes and sizes seen in the papillary

dermis (100%) (Figure 3a). Other nonspecific features included, acanthosis (20%) and epidermal atrophy (10%). Other findings in the dermis include solar elastosis (50%), perivascular infiltrate of lymphocytes (50%), and presence of telangiectasia (40%) (Figure 3b).

## Discussion

The term Ochronosis was first described in 1866 by Virchow. This was used to describe ochre colored pigments located in connective tissues of various organs [7]. It was in 1975 when Findlay et al<sup>4</sup> first described this condition as an epidemic in Transvaal South Africa due to overuse of topical hydroquinone.

Its exact incidence globally remains unknown. However, the largest case series reported was in South Africa where 28-35% of the black population were affected by exogenous ochronosis due to hydroquinone containing products. However, its increasing incidence has also been seen in Asia [7, 8].

The exact pathogenesis of exogenous ochronosis remains unknown. However, a theory on its etiology was described by Penny's et al<sup>9</sup> and is still the most acceptable theory being used to date. It is hypothesized that hyperpigmentation is due hydroquinone's competitive inhibition of homogentisic oxidase. This leads to formation and accumulation of homogentisic acid and other metabolic products that polymerizes to form ochronotic pigments deposited in the papillary dermis [7,10]. Another study done in 2019 at Boston University showed that tyrosinase inhibition of hydroquinone also plays a role on histopath findings in EO. This inhibition leads to decreased photoprotection leading to deeper penetration of UV radiation and solar elastosis [11]. These findings translate clinically as gray-brown, blue black macules or papulonodules (ochronotic pigments) on the background of chronically sun damaged skin (solar elastosis) on sun exposed areas and osseous surfaces [7].

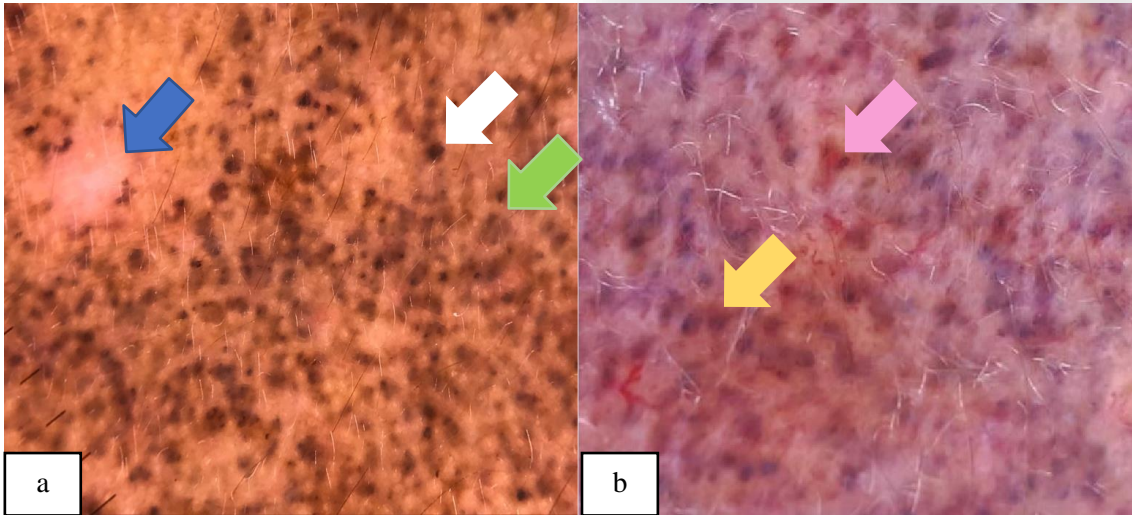


Figure 2a blue gray and black dots (white arrow); annular and arcuate structures (green arrows) confetti- like depigmentation (blue arrow).  
 Figure 2b reddish to dark brown curvilinear structures (yellow arrow); telangiectasia (pink arrow).

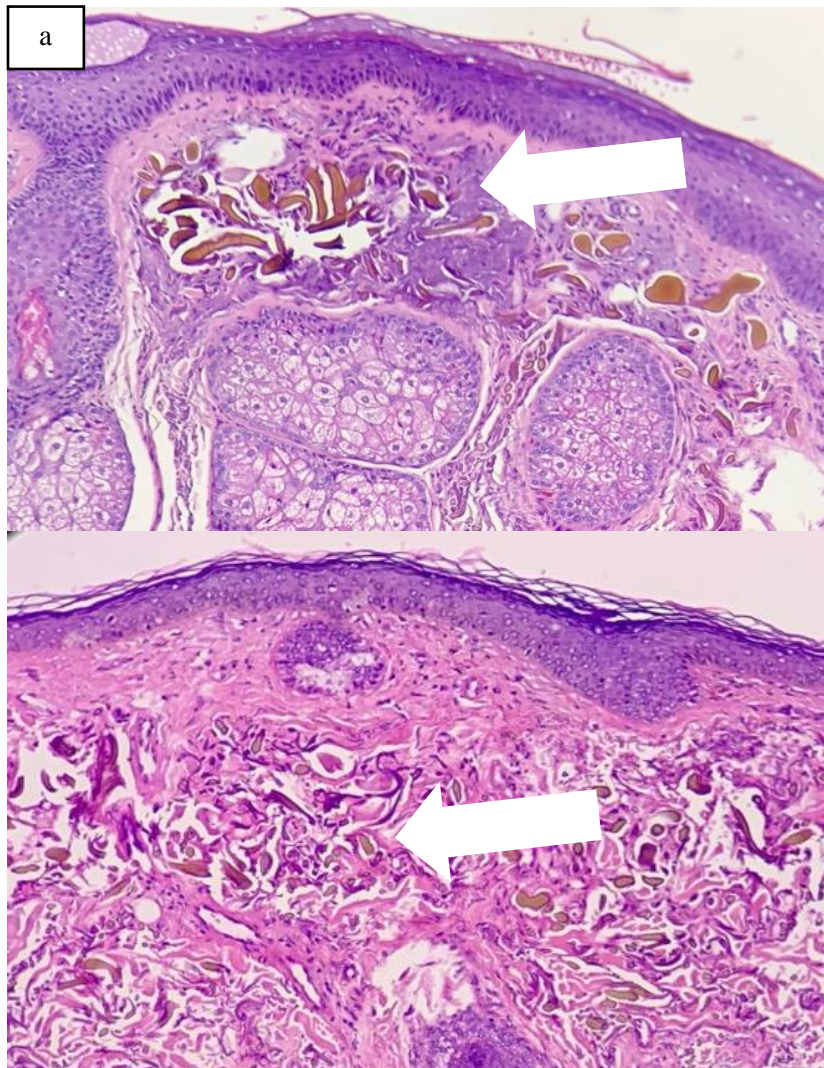


Figure 3a LPO view; Diagnostic finding of ochre colored bodies (white arrow)

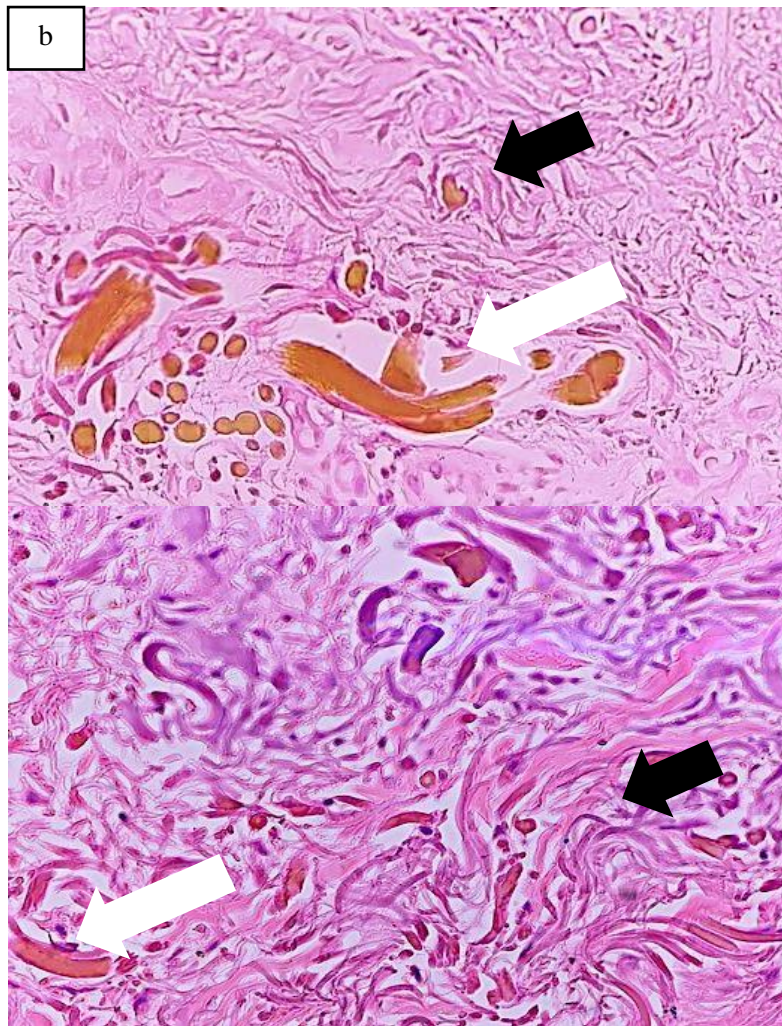


Figure 3b HPO view; Ochre colored bodies (white arrow), Solar elastosis (black arrow)

Many factors like UV exposure, prolonged use of hydroquinone containing products, outdoor activities and amount of the product applied have been identified for a patient to develop EO [7]. Even at low concentrations of hydroquinone (2%), EO has been reported. This occurrence was also found in our patients who used the 2% concentration. All of them did experience this untoward complication which implies that the concentration of hydroquinone may not be a key player in the development of EO. The presence and interplay of other factors mentioned might also be evident. A study in Asia purported that it is the extended use of hydroquinone that caused this condition more than its concentration [8]. Exogenous ochronosis is commonly seen in females due to

hormonal factors that heighten their propensity for hyperpigmentation disorders such as melasma. An in vitro study showed that 17 $\beta$  estradiol concentrations in pregnancy and ethinyl estradiol which is often used in oral contraceptive pills, combined with UVB exposure were identified to increase melanin production leading to hyperpigmentation disorders [12]. Estradiol, luteinizing hormone and follicle-stimulating hormone levels were identified to be higher in women with melasma compared to those without [13]. This may explain the heightened use of topical lightening agents that lead to abuse and complications [6]. As all of our patients are Filipino who all reside in the Philippines which is a tropical country, daily UV exposure combined with hormonal influences might account for the demographic

data presented in this case series. Majority of our patients were female who used topical hydroquinone containing whitening agents for a mean duration of 5.3 years without sun protection. Similar to the systematic review on hydroquinone-associated ochronosis done in 2020, which reported that middle-aged women were majority of patients (53.2%) who used hydroquinone for a mean duration of 5 years [14].

Clinically, exogenous ochronosis manifests as asymptomatic gray-brown or blue-black macules on the cheeks, temples and neck [5]. However, during its early stages it may easily mimic melasma. Distinguishing between the two proves to be important as observed worsening of pigmentation may lead to increased application of lightening products that may worsen EO. Clinical clues such as, a patient's chronic use of hydroquinone, facial hyperpigmentation unresponsive to usual treatment, coarse texture of the skin, fine telangiectasia and hyperchromia with "speckling" are features that may alert us to screen the patient for exogenous ochronosis [15]. Clinching the correct diagnosis can help us manage patient expectations and outcomes. The gold standard for diagnosis remains to be a skin punch biopsy, however dermoscopy has been useful to identify peculiar findings in exogenous ochronosis that may help in securing the diagnosis [15, 16]. Large scale studies on dermoscopy findings of EO have not been done to the best of our knowledge. However, finding of typical blue-gray amorphous areas obliterating follicular openings have been reported in EO together with irregular brown-gray globular, annular and arciform structures, worm-like structures and white dots. As opposed to finding dark brown reticular pattern-accentuation, sparing follicles and sweat gland openings in melasma [10, 15]. Our patient's clinical and dermoscopy presentation are very much similar to EO. Its presentation clinically as blue-gray in color is due to the pigment's location in the dermis (Tyndall

effect). These findings in dermoscopy correlates with the histology showing the yellow-brown or ochre banana-shaped fibers in the papillary dermis.

To date, there are still no treatment guidelines for exogenous ochronosis. Various therapeutic trials have been done however results have been varied. EO remains to be difficult to treat and early discontinuation of the offending agent, hydroquinone, is the cornerstone of management. Therefore, early diagnosis must be made in order to prevent worsening of lesions.

## Reference

1. Hu Y, Zeng H, Huang J, Jiang L, Chen J, Zeng Q. Traditional Asian herbs in skin whitening: the current development and limitations. *Frontiers in Pharmacology*. 2020 Jul 7; 11:982.
2. Al-Sarraf A, Bewley A, De Luca I, Prilutskaya M, Corazza O. Image enhancing drugs: a narrative review on the motivational risk factors influencing skin lightening use. *Emerging Trends in Drugs, Addictions, and Health*. 2021 Jan 1; 1:100009.
3. Draelos ZD. Skin lightening preparations and the hydroquinone controversy. *Dermatologic Therapy*. 2007 Sep;20(5):308-13.
4. Findlay GH, Morrison JG, Simson IW. Exogenous ochronosis and pigmented colloid milium from hydroquinone bleaching creams. *British Journal of Dermatology*. 1975 Dec 1;93(6):613-22.
5. Kramer KE, Lopez A, Stefanato CM, Phillips TJ. Exogenous ochronosis. *Journal of the American Academy of Dermatology*. 2000 May 1;42(5):869-71.
6. Sindhu CS, Babitha C, Priyadarshini A, Veeraraghavan M. Exogenous ochronosis in an elderly Indian male: A case report. *Pigment International*. 2019 Jan 1;6(1):33-6.

7. Bhattar PA, Zawar VP, Godse KV, Patil SP, Nadkarni NJ, Gautam MM. Exogenous ochronosis. *Indian Journal of Dermatology*. 2015 Nov;60(6):537.
8. Liu WC, Tey HL, Lee JS, Goh BK. Exogenous ochronosis in a Chinese patient: use of dermoscopy aids early diagnosis and selection of biopsy site. *Singapore Medical Journal*. 2014 Jan;55(1): e1.
9. Penneys NS. Ochronosislike pigmentation from hydroquinone bleaching creams. *Archives of Dermatology*. 1985 Oct 1;121(10):1239-40.
10. Romero SA, Pereira PM, Mariano AV, Francesconi F, Francesconi VA. Aplicação da dermatoscopia no auxílio diagnóstico da ocronose exógena. *Anais Brasileiros de Dermatologia*. 2011; 86:31-4.
11. Ho JD, Vashi N, Goldberg LJ. Exogenous ochronosis as an elastotic disease: a light-microscopic approach. *The American Journal of Dermatopathology*. 2020 Aug 1;42(8):571-7.
12. Cario M. How hormones may modulate human skin pigmentation in melasma: An in vitro perspective. *Experimental Dermatology*. 2019 Jun;28(6):709-18.
13. K Mahmood, M. Nadeem, S. Aman, A. Hameed, A. H. Kazmi, *Asianet-Pakistan*, 2012. [cited 2018 Apr 24] <https://doi.org/trove.nla.gov.au/work/161673123>
14. Ishack S, Lipner SR. Exogenous ochronosis associated with hydroquinone: a systematic review. *International Journal of Dermatology*. 2022 Jun;61(6):675-84.
15. Khunger N, Kandhari R. Dermoscopic criteria for differentiating exogenous ochronosis from melasma. *Indian Journal of Dermatology, Venereology and Leprology*. 2013 Nov 1; 79:819.
16. Martins VM, Sousa AR, Portela ND, Tigre CA, Gonçalves LM, Castro Filho RJ. Exogenous ochronosis: case report and literature review. *Anais Brasileiros de Dermatologia*. 2012; 87:633-6.