



**JOURNAL**  
OF  
ASIA PACIFIC AESTHETIC SCIENCES

# **JOURNAL OF ASIA PACIFIC AESTHETIC SCIENCES**

**MAY 2022, VOLUME 2, ISSUE 1**



**E-ISSN: 2805 - 4482**

[www.japa-edu.org](http://www.japa-edu.org)



**Editor in Chief:** Assoc. Prof. Dr Ungku Mohd Shahrin Mohd Zaman, MD  
**Associate Editors:** Assoc. Prof Dr. Ernieda Md Hatah, PhD

## Editorial Board

### International

**Dr Omer Buhsem**  
(Turkish Aesthetic Surgery Society, Turkey)

**Dr Tae Hwan Ahn**  
(Korean Association for Laser, Dermatology & Trichology (KALDAT), Korea)

**Dr Anuj Pall**  
(Escallent Institute of Laser & Aesthetic Medicine (EILAM), India)

**Dr Kenneth Thean**  
(Ensoul Medical Centre, Singapore)

**Dr Reza Yuridian Purwoko**  
(University of Indonesia, Indonesia)

**Dr Johannes Dayrit**  
(De La Salle Medical & Health Sciences Institute, Philippines)

### Local

**Prof. Dr Wan Azman b. Wan Sulaiman**  
(Universiti Sains Malaysia)

**Assoc. Prof. Dr Adibah Hanim bt Ismail**  
(Universiti Putra Malaysia)

**Dr Daniel Looi Qi Hao**  
(University of Malaya)

**Assoc. Prof. Dr Shah Jumaat b. Mohd Yussof**  
(Universiti Teknologi Mara)

**Assoc. Prof. Dr Tarita bt Taib**  
(Universiti Teknologi Mara)

**Dr Meera Kuppusamy**  
(Universiti Teknologi Mara)

**Dr Nurhanan Murni bt. Yunos**  
(Forest Research Institute Malaysia, FRIM)

**Dr Faizal Ali**  
(Johor Specialist Hospital)

## Secretariat

**Noor Shahirah bt. Suparji**  
**Muhammad Farhan b. Abdul Rashid**  
**Nur Izzati bt. Mohd Shahrol**

\*The Journal Asia Pacific Aesthetic Sciences (JAPA) (ISSN 2805-4482) is a three-times-a-year peer-reviewed, open-access, fully online journal

**Editorial Office:** S62-1, Red Carpet Avenue, Encorp The Strand, Kota Damansara PJU 5/22, 47810 Petaling Jaya, Selangor

**Homepage:** [www.japa-edu.org](http://www.japa-edu.org)  
**Email:** [admin@japa-edu.org](mailto:admin@japa-edu.org)  
**Telephone:** +603 6151 8700 / +6016 626 7078



## THE JOURNEY BEGIN

Since the inaugural issue of the *Journal of Asia Pacific Aesthetic Sciences (JAPA)*, the editorial board has received very encouraging support from aesthetic, pharmaceutical and regenerative communities, including the *Medical Aesthetic Division, Ministry of Health, Malaysia*. There were manuscripts submitted not only from Malaysia but also from other countries such as Turkey and the Philippines. These manuscripts encompass wide-ranging topics on aesthetic, pharmaceutical and regenerative medicine with data from wards, clinics, laboratories, and households in different types of communities.

As JAPA grows from infancy to early childhood, we aspire to strengthen the scientific rigour of the manuscripts. We should take pride that our empirical work can withstand the scrutiny of critical reviews from within and outside the country. In the same spirit of upgrading ourselves, we should also work towards attracting more articles from abroad, especially from the Asia Pacific region.

It is our aspiration for the journal to be indexed locally and internationally. To begin with, we are glad to announce that recently JAPA was accepted to be included in MyCite (Malaysia Citation portal) and hopefully by other worldwide reputable organisations in the future. We realise there is still a great deal of work needed to build up the scientific worthiness and timeliness of the journal, among other imperatives. We need to set our vision on the high value of being placed on citations of publications in the world ranking as citations imply our data is worth quoting and indicate that the authors are prepared to defend the intellectual content of their manuscript.

On behalf of the editorial board, I wish to convey my appreciation to all authors, reviewers and JAPA secretariat staff who have given their support towards the success of this publication.

**Dr Ungku Mohd Shahrin b Mohd Zaman, MD**

*Editor-In-Chief*



**JOURNAL OF ASIA PACIFIC AESTHETIC SCIENCES**  
Copyright @ 2021 by **Esthetic Medical Solution Sdn Bhd**

All rights reserved. No part of this publication may be reproduced or transmitted in any form or by any means, electronic or mechanical, including photocopy, recording, or any information storage and retrieval system, without written permission from the publisher.

**Copyright notice**

Upon acceptance of an article, authors will be asked to transfer copyright. This transfer will ensure the widest possible dissemination of information. A letter will be sent to the corresponding Author confirming receipt of the manuscript.

If excerpts from other copyrighted works are included, the Author(s) must obtain written permission from the copyright owners and credit source(s) in the article

ISSN 2805-4482

Published by: Esthetic Medical Solution Sdn Bhd



Editorial

- ii      **The Journal of Asia Pacific Aesthetic Sciences's Editor in-Chief**

Review Articles

- 1      **Standardisation of Platelet-Rich Plasma in Clinical Practice**  
*Mohamad Aizat Rosli, Shah Jumaat Mohd Yussof, Normala Basiron, Wan Azman Wan Sulaiman*

Case Report

- 10      **Secreted Trophic Factors of Mesenchymal Stem Cells Support Avascular Wound Recovery in A Patient with Vascular Occlusion: Case Report**  
*Ch'ng C.N, Koh, K. Y & Lim, W. K*
- 16      **Addressing Keloid and Hypertrophic Scars from Hair Transplant: A Case Report**  
*Inderjit Kaur, MBBS, ABHRS*
- 22      **Rhinophyma in Three Filipino Gentlemen which Showed Remarkable Improvement Using a Combination of Low Dose Oral Isotretinoin, Long Pulsed 1064-nm neodymium-yttrium-aluminum-garnet (Nd:YAG) Laser and Carbon Dioxide Laser**  
*Johannes Flores Dayrit, MD & Julius Garcia Gatmaitan, MD*
- 29      **A Nasal Dorsal Mucosal Cyst After Rhinoplasty**  
*Ummut Tuncel*

## Standardisation of Platelet-Rich Plasma in Clinical Practice

Mohamad Aizat Rosli<sup>1,3</sup>, Shah Jumaat Mohd Yussof<sup>2</sup>, Normala Basiron<sup>1</sup>, Wan Azman Wan Sulaiman<sup>3</sup>

---



<sup>1</sup>Department of Plastic and Reconstructive Surgery, Hospital Kuala Lumpur, Jalan Pahang, 50586 Kuala Lumpur, Malaysia

<sup>2</sup>Plastic Reconstructive & Aesthetic Surgery Unit, Faculty of Medicine, UiTM, Kampus Puncak

Alam, 42300 Puncak Alam, Selangor, Malaysia

<sup>3</sup>Reconstructive Sciences Unit, School of Medical Sciences, Medical Campus, Universiti Sains Malaysia, 16150 Kota Bharu, Kelantan, Malaysia

### Abstract

Platelet-Rich Plasma (PRP) has been widely used in many medical fields, including aesthetic medicine. It has gained popularity owing to the knowledge that PRP can promote wound healing and facilitate scar improvement or facial rejuvenation. Unfortunately, the evidence supporting PRP remains elusive due to inconsistencies in the literature and lack of standardisation in the PRP preparation protocols, administration, and documentation. Since its introduction, many authors have attempted to classify PRP, however until today; no consensus has been reached due to the confusion in the nomenclatures. PRP administration has also become a blind process whereby varying volumes or constituents of PRP are used, causing unpredictable and inconsistent outcomes. We aim to highlight this issue and call for standardisation in PRP administration protocol.

**Keywords:** Platelet-Rich Plasma, PRP, Classification, Aesthetic

*Address of corresponding author:*

*Plastic Reconstructive & Aesthetic Surgery Unit, Faculty of Medicine, UiTM Kampus Sg. Buloh, 47000 Sg. Buloh, Selangor, Malaysia*

*Email:*

*shahjumaat@uitm.edu.my*

*Received: January 18, 2022*

*Revision received: March 10, 2022*

*Accepted after revision: March 21, 2022*

*www.japa-edu.org*



Recently, there has been a surge of platelet-rich plasma (PRP) usage for various indications in many medical fields, including dermatology, cardiology, plastic surgery, anesthesia, orthopedics, spine and sports medicines (Frautschi et al., 2017; Collins et al. 2021; Kelm and Ibrahim, 2022). PRP has also been getting much attention in the aesthetic world, as shown in Figure 1, mainly due to widespread commercial interest and social media (Kelm and Ibrahim, 2022). It is commonly used as an adjunct to augment the effect of blepharoplasty, micro-needling, facelift, fractional carbon dioxide laser, hair transplantation and fat grafting (Frautschi et al., 2017; Alves and Grimalt, 2017; Kelm and Ibrahim, 2022). PRP can also be used as a standalone product in its topical or injectable form to promote skin rejuvenation, scar improvement, depigmentation, wound healing and hair growth in alopecia (Frautschi et al., 2017; Alves and Grimalt, 2017; Kelm and Ibrahim, 2022). PRP utilization stems from the understanding that platelet-derived growth factors and cytokines promote wound healing and play critical roles in all three phases of the repair cascade: inflammation, proliferation, and remodeling (Everts et al., 2020; Kelm and Ibrahim, 2022).

However, there is a paucity in the evidence as most reported beneficial outcomes are anecdotal. Although the theoretical potentials of PRP were supported by many *in vitro* studies, the *in vivo* evidence remains inconclusive (Harrison and Alsousou, 2020). Researchers still cannot strongly validate the PRP advantageous effects in the human population because most evaluations of the different PRP preparations were derived from small case series, cohort studies without adequate control groups, or poorly designed clinical trials (Platelet-rich Plasma for Facial Rejuvenation (PPFPR), 2017). They often have unclear documentation on the PRP bio-formulations used, inconsistent dosing, and a lack of objective outcome measurements. Many

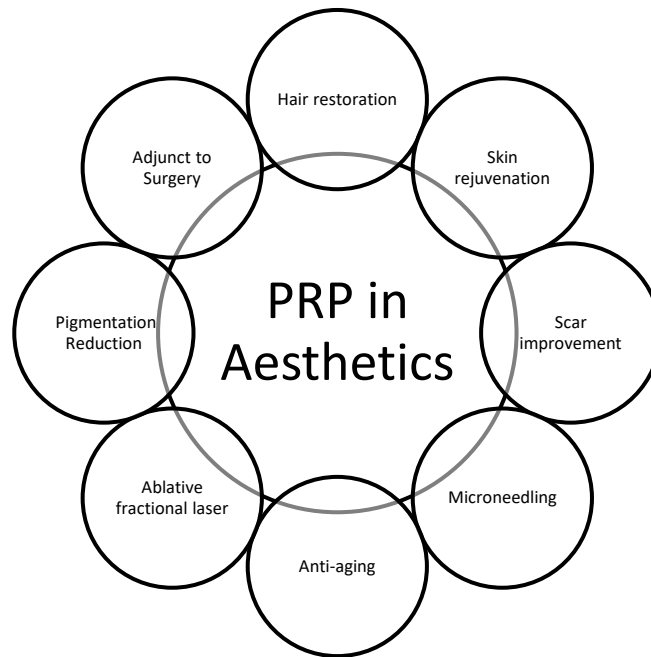
systematic reviews also failed to find standardization in the PRP protocols available in the literature (Frautschi et al., 2017; PPFPR, 2017; Evert et al., 2020; Evans et al., 2022; Gentile and Garcovich, 2022; Kelm and Ibrahim, 2022).

These vast inconsistencies in the clinical practice are further compounded by the absence of clear regulations and legislation on PRP, the abundance of commercially available PRP preparation systems producing varying PRP compositions, and the lack of clear protocols for administering PRP (Fadadu et al, 2020; Evans et al., 2022; Gentile and Garcovich, 2022; Kelm and Ibrahim, 2022). Hence, the practicality of PRP is now questionable due to the heterogeneity of the evidence present.

### **The Basics of PRP Therapy**

Platelet-rich plasma (PRP) is an autologous blood product created via centrifugation of whole blood, with the concentration of platelets usually five-fold greater than normal physiological levels. PRP was first used in the 1970s by hematologists as a transfusion product in thrombocytopenic patients, before making its way into other specialties (Collins et al, 2021; Kelm and Ibrahim, 2022).

The platelet's roles in wound healing cascade have been well studied. Platelets contain a rich source of growth factors and cytokines, including platelet-derived growth (PDGF), transforming growth factor (TGF) and vascular endothelial growth factor (VEGF). Following platelet activation, these factors are released, regulating cell proliferation, chemotaxis and angiogenesis. The provisional fibrin matrix formed also supports cellular migration, proliferation and differentiation (Evert et al., 2020). The justification for PRP treatment is that the injection of concentrated platelets containing plasma at the injury sites will accelerate wound healing and tissue



**Figure 1:** PRP utilization in Aesthetic Medicine

regeneration by releasing a supraphysiological amount of growth factors and cytokines mentioned above (Evert et al., 2020; Kelm and Ibrahim, 2022).

The ability of PRP to facilitate the synthesis of collagen and elastin, and stimulate follicular development allows PRP to be an attractive option for aesthetic and anti-aging treatment (Kelm and Ibrahim, 2022). The ability of PRP to facilitate the synthesis of collagen and elastin, and stimulate follicular development allows PRP to be an attractive option for aesthetic treatment (Evans et al., 2022; Gentile and Garcovich, 2022; Kelm and Ibrahim, 2022). In hair growth, the growth factors released from the platelet can increase the transition from telogen to anagen, induce dermal cells proliferation, and promote hair follicle maturation. In skin rejuvenation, the available evidence suggests that PRP can soften the wrinkles, reduce the scar and pigmentation appearance, as well as accelerate wound healing (Kelm and Ibrahim, 2022).

Although there is no single standardized PRP protocol, most preparations follow these fundamental steps: (1) blood collection from the patient through venepuncture; (2) centrifugation to separate red blood cells and

platelet-poor plasma from the ‘buffy coat’, a layer rich in white blood cells (WBCs) and platelets; (3) plasma aspiration; (4) potential second centrifugation to separate the White Blood Cells (WBCs) depending on the intent whether to keep or remove the WBCs; (5) selected supernatant removal; (6) mixing/resuspension of platelets; (7) activation with calcium chloride, thrombin or another agent; and (8) application (Frautschi et al., 2017; Fadadu et al., 2020).

### **The Rationale for Standardization in Clinical Practice**

The PRP’s platelet, WBCs, and growth factors concentration can differ significantly depending on the centrifugal spinning and preparation protocols (Kelm and Ibrahim, 2022). Two recent systematic reviews on PRP in alopecia found heterogeneous PRP preparation protocols in their analysis, with substantial variability depending on the commercial PRP kits used, concentration and volume administered, and injection details (Evans et al., 2022; Gentile and Garcovich, 2022). The exact constituents of the PRP, or so-called the “PRP dose” administered to the patients, can also vary based on the individual clinician practice (Evans et al., 2022; Gentile



and Garcovich, 2022). Some preparations may also be contaminated with red blood Cells (RBCs) (Evert et al.,2020).

As for the individual cellular composition of PRP, a dose-dependent relationship has been previously reported in platelet, suggesting a linear relationship between the platelet concentration and mesenchymal stem cells growth, fibroblasts proliferation, and collagen formation (Frautschi et al., 2017). The role of WBCs in PRP has also been controversial and subjected to ongoing debates. Some studies showed a positive effect of the WBC's cytokines from the antimicrobial properties and increased VEGF level, while others reported adverse effects from the reactive oxygen species they release, causing inflammation and tissue damage (Frautschi et al.,2017). When applied to local tissue, PRP containing RBCs can cause eryptosis or suicidal erythrocyte death. This response triggers the release of macrophage migration inhibitory factors, which inhibit stem cells' migration and fibroblast proliferation (Evert et al.,2020).

As we understand more about the role of platelet concentration, WBC's influence, and the deleterious effect of RBC, several attempts to characterize the PRP processed manually or from the commercially available systems have been made. Fadadu et al. reported no standardization in all thirty-three PRP

preparation systems they studied. The final cellular concentration also varied significantly across the systems. In addition, only eleven systems met the definition of PRP as defined by Marx et al. as having a minimum platelet concentration of 1 000 000 platelets/ $\mu$ L, and only ten systems met the criteria that PRP should have a concentration of at least five times than the baseline. Surprisingly, 3 of the 33 systems reviewed even produced PRP with platelet counts less than the whole blood baseline level (Fadadu et. al., 2019)

Many studies do not document the concentration of platelets within the patient's baseline whole blood and the final PRP preparations, and it is also being reflected in our daily clinical practice (Frautschi et al., 2017). PRP administration has become a blind process where unknown volumes or concentrations of active bio formulations are used. Inadvertently, even if there are any tangible good outcomes, they are often inconsistent and subjected to presumption (Frautschi et al., 2017).

However, in practice, we are aware that the precise determination of the PRP compositions is not straightforward. The terminology is somewhat confusing, and many reports in aesthetic use the broad term of PRP for simplicity. Several authors have attempted to classify PRP formulation (Table 1).

**Table 1:** PRP Classification

<b>Author (year)</b>	<b>Classification</b>
Ehrenfest et al. (2009)	Leukocyte-Fibrin density
DeLong et al. (2012)	PAW
Mautner et al. (2015)	PLRA
Magalon et al. (2016)	DEPA
Lana et al. (2017)	MARSPILL

Dohan Ehrenthet et al. in 2009 classified the PRP according to 2 qualitative parameters: presence or absence of cell content (such as leucocytes) and the fibrin architecture, namely pure platelet-rich plasma (P-PRP), leukocyte and platelet-rich plasma (L-PRP), pure platelet-rich fibrin (P-PRF), and leukocyte and platelet-rich fibrin (L-PRF), as shown in Table 2. However, as it did not consider the role of other cellular subpopulations such as RBCs and neutrophils (Collins et al, 2021), DeLong et al. introduced a more quantitative classification, the PAW classification (Platelets, Activation, White blood cells) in 2012, as depicted in Figure 2. Unfortunately, the PAW classification still did not address the role of RBC; hence Mautner et al. in 2015 proposed the PLRA classification (Platelet count, Leukocyte content, RBC content, activation) as illustrated in Table 3, which was the first system to specify the volume of PRP administered and the absolute platelet concentration. In 2016, Magalon et al. proposed another classification system based on the quality of the preparation, the DEPA classification (Dose, Efficiency, Purity, Activation), as illustrated in Table 4. It analyses some additional aspects of the preparation process (efficiency and purity). However, it does not address the critical quantitative measurement of the different cell types as the PLRA (Collins et al.,2021).

The latest classification, introduced by Lana et al., was the MARSPILL classification (Method, Activation, RBCs, Spin, Platelet concentration, Image guidance, Leukocyte concentration, Light activation). As demonstrated in Table 5, it incorporates several aspects of the manufacturing process and the subgroups of cellular components. They also introduced the novel concept of light activation and image guidance in administering the PRP (Lana et al.,2017). Nonetheless, the final element of this classification is probably not applicable in some aesthetic procedures, such

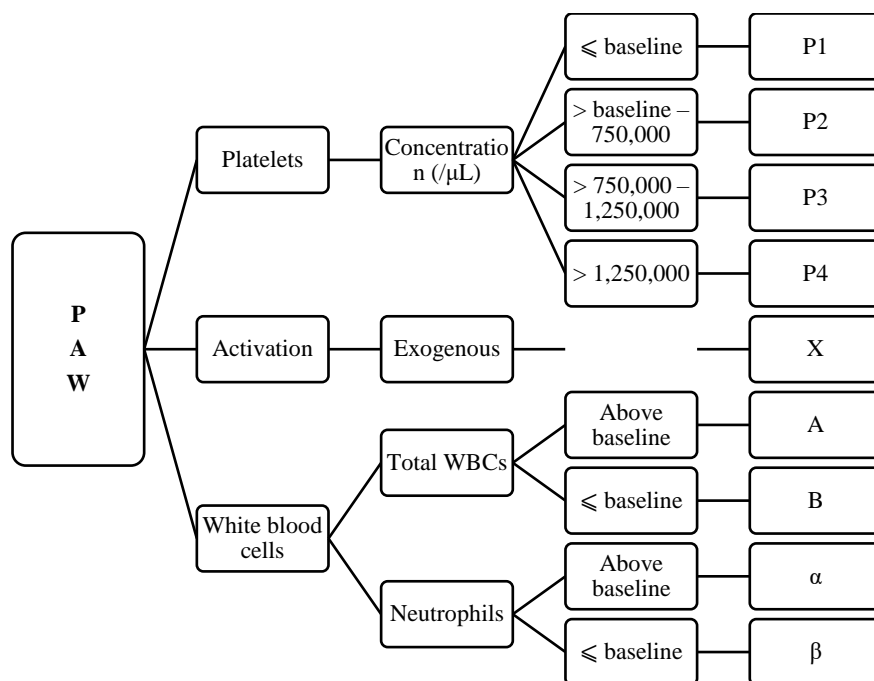
as the application of PRP following laser or micro-needling treatments.

Despite these classifications, none of these systems is universally accepted or used extensively as they are still unable to address the variability in the production protocols and the ongoing confusion with the nomenclatures among clinicians (Rossi et al.,2019).

The need for standardization in PRP formulations can probably be met by freeze-drying PRP (FD-PRP). Freeze-drying, or lyophilization, is a technology of freezing followed by water sublimation and subsequent removal of water vapor (Andia et al., 2020). Freeze-dried PRP (FD-PRP) can be prepared on an autologous basis or derived from a single or pooled healthy donors to produce allogenic FD-PRP, often followed by sterilization by gamma radiation (Andia et al., 2020).

The quality of FD-PRP is determined by the platelet integrity and the activity of plasma coagulation factors or cytokines after rehydration. Andia et al. showed that freeze-drying preserves the platelet function, cytokine concentration, and function (Andia et al., 2020). This technology can accurately determine the platelet concentration and cytokine growth factor levels, facilitating standardized treatment protocols. FD-PRP can also be formulated to achieve specific parameters or concentrations and fabricated by combining with other biomaterials or elements to control the cytokine release and match the specific local tissue requirement. Besides, FD-PRP is stable at room temperature and can be stored for several months (Andia et al., 2020).

Despite the advantages, the high cost of FD-PRP production and limited processing and storage facilities may be the limiting factors (Andia et al., 2020). Nevertheless, this is an alternative worth exploring in the quest for consistency and standardization in PRP therapy.



**Figure 2:** PLRA Classification (2015)

**Table 2:** Ehrenfest classification (2009)

Preparation		Leukocyte	Fibrin Density
<b>P-PRP</b>	Pure platelet-rich plasma	Poor	Low
<b>L-PRP</b>	Leukocyte and platelet-rich plasma	Rich	Low
<b>P-PRF</b>	Pure platelet-rich fibrin	Poor	High
<b>L-PRF</b>	Leukocyte and platelet-rich fibrin	Rich	High

**Table 3:** PLRA Classification (2015)

Criteria		Final Score
<b>Platelet count</b>	____P	____M
	Volume Injected	Cells/μL
<b>Leucocyte content</b>	> 1%	+
	< 1%	–
<b>Red blood cell content</b>	> 1%	+
	< 1%	–
<b>Activation</b>	Yes	+
	No	–

**Table 4:** DEPA Classification (2016)

Criteria	Subgroup	Description
Dose of injected platelets	A: Very high	> 5 Billion injected platelets
	B: High	3–5 Billion injected platelets
	C: Medium	1–3 Billion injected platelets
	D: Low	< 1 Billion injected platelets
Efficiency of production	A: High	Recovery rate in platelets > 90%
	B: Medium	Recovery rate in platelets 70–90%
	C: Low	Recovery rate in platelets 30–70%
	D: Poor	Recovery rate in platelets < 30%
Purity of PRP	A: Very pure	Platelets in PRP > 90%
	B: Pure	Platelets in PRP 70–90%
	C: Heterogenous	Platelets in PRP 30–70%
	D: Whole blood	Platelets in PRP < 30%
Activation process	-	Autologous thrombin Calcium chloride

**Table 5:** MARSPILL Classification (2017)

Acronym	Description
Method	Handmade (H)
	Machine (M)
Activation	Activated (A+)
	Not activated (A-)
Red blood cells	Rich (RBC-R)
	Poor (RBC-P)
Spin	One spin (Sp1)
	Two spins (Sp2)
Platelet number	<b>Folds from baseline:</b>
	PL 2–3
	PL 4–6
	PL 6–8
	PL 8–10
Image guided	Guided (G+)
	Not guided (G-)
Leukocyte concentration	Rich (Lc-R)
	Poor (Lc-P)
Light activation	Activated (A+)
	Not Activated (A-)

## Conclusion

We strongly believe that standardization of PRP therapy is the most crucial step in determining the efficacy of PRP in aesthetic surgery and other specialities. Future studies must address

all the variables in PRP preparation to facilitate consistency in outcome reporting. With this, large-scale RCTs can be undertaken to compare the therapeutic effects between different PRP preparation protocols, concentrations, amounts, and techniques used.

## Conflict of interest

None to declare

## Funding

No funding received

## References

1. Alves, R., & Grimalt, R. (2018). A Review of Platelet-Rich Plasma: History, Biology, Mechanism of Action, and Classification. *Skin appendage disorders*, 4(1), 18–24. <https://doi.org/10.1159/000477353>
2. Andia, I., Perez-Valle, A., Del Amo, C., & Maffulli, N. (2020). Freeze-Drying of Platelet-Rich Plasma: The Quest for Standardization. *International journal of molecular sciences*, 21(18), 6904. <https://doi.org/10.3390/ijms21186904>
3. Collins, T., Alexander, D., & Barkatali, B. (2021). Platelet-rich plasma: a narrative review. *EFORT open reviews*, 6(4), 225–235. <https://doi.org/10.1302/2058-5241.6.200017>
4. DeLong, J. M., Russell, R. P., & Mazzocca, A. D. (2012). Platelet-rich plasma: the PAW classification system. *Arthroscopy : the journal of arthroscopic & related surgery : official publication of the Arthroscopy Association of North America and the International Arthroscopy Association*, 28(7), 998–1009. <https://doi.org/10.1016/j.arthro.2012.04.148>
5. Dohan Ehrenfest, D. M., Rasmusson, L., & Albrektsson, T. (2009). Classification of platelet concentrates: from pure platelet-rich plasma (P-PRP) to leucocyte- and platelet-rich fibrin (L-PRF). *Trends in biotechnology*, 27(3), 158–167. <https://doi.org/10.1016/j.tibtech.2008.11.009>
6. Evans, A. G., Mwangi, J. M., Pope, R. W., Ivanic, M. G., Botros, M. A., Glassman, G. E., Pearce, F. B., Jr, & Kassis, S. (2022). Platelet-rich plasma as a therapy for androgenic alopecia: a systematic review and meta-analysis. *The Journal of dermatological treatment*, 33(1), 498–511. <https://doi.org/10.1080/09546634.2020.1770171>
7. Everts, P., Onishi, K., Jayaram, P., Lana, J. F., & Mautner, K. (2020). Platelet-Rich Plasma: New Performance Understandings and Therapeutic Considerations in 2020. *International journal of molecular sciences*, 21(20), 7794. <https://doi.org/10.3390/ijms21207794>
8. Fadadu, P. P., Mazzola, A. J., Hunter, C. W., & Davis, T. T. (2019). Review of concentration yields in commercially available platelet-rich plasma (PRP) systems: a call for PRP standardization. *Regional anesthesia and pain medicine*, rapm-2018-100356. <https://doi.org/10.1136/rapm-2018-100356>
9. Frautschi, R. S., Hashem, A. M., Halasa, B., Cakmakoglu, C., & Zins, J. E. (2017). Current Evidence for Clinical Efficacy of Platelet Rich Plasma in Aesthetic Surgery: A Systematic Review. *Aesthetic surgery journal*, 37(3), 353–362. <https://doi.org/10.1093/asj/sjw178>
10. Gentile, P., & Garcovich, S. (2022). Systematic review: The platelet-rich plasma use in female androgenetic alopecia as effective autologous treatment of regenerative plastic surgery. *Journal of plastic, reconstructive & aesthetic surgery : JPRAS*, 75(2), 850–859. <https://doi.org/10.1016/j.bjps.2021.11.004>
11. Harrison, P., & Alsousou, J. (2020). Studies on platelet rich plasma - new editorial policy for "Platelets". *Platelets*, 31(3), 281–282. <https://doi.org/10.1080/09537104.2020.1729013>
12. Kelm, R. C., & Ibrahim, O. (2022). Utility of platelet-rich plasma in aesthetics. *Clinics in dermatology*, 40(1), 19–28. <https://doi.org/10.1016/j.clindermatol.2021.08.007>
13. Lana, J., Purita, J., Paulus, C., Huber, S. C., Rodrigues, B. L., Rodrigues, A. A., Santana, M. H., Madureira, J. L., Jr, Malheiros Luzo, Â. C., Belangero, W. D., & Annichino-Bizzacchi, J. M. (2017). Contributions for classification of platelet rich plasma - proposal of a new classification: MARSPILL. *Regenerative medicine*, 12(5), 565–574. <https://doi.org/10.2217/rme-2017-0042>
14. Magalon, J., Chateau, A. L., Bertrand, B., Louis, M. L., Silvestre, A., Giraudo, L.,

- Veran, J., & Sabatier, F. (2016). DEPA classification: a proposal for standardising PRP use and a retrospective application of available devices. *BMJ open sport & exercise medicine*, 2(1), e000060. <https://doi.org/10.1136/bmjsem-2015-000060>
15. Mautner, K., Malanga, G. A., Smith, J., Shiple, B., Ibrahim, V., Sampson, S., & Bowen, J. E. (2015). A call for a standard classification system for future biologic research: the rationale for new PRP nomenclature. *PM & R : the journal of injury, function, and rehabilitation*, 7(4 Suppl), S53–S59. <https://doi.org/10.1016/j.pmrj.2015.02.005>
  16. Platelet-rich Plasma For Facial Rejuvenation (2017, Health Technology Assessment Section, Medical Development Division, Ministry of Health Malaysia, 004/2017. Retrieved from [https://www.moh.gov.my/index.php/database\\_stores/store\\_view\\_page/30/304?print=1](https://www.moh.gov.my/index.php/database_stores/store_view_page/30/304?print=1)
  17. Rossi, L. A., Murray, I. R., Chu, C. R., Muschler, G. F., Rodeo, S. A., & Piuze, N. S. (2019). Classification systems for platelet-rich plasma. *The bone & joint journal*, 101-B(8), 891–896. <https://doi.org/10.1302/0301-620X.101B8.BJJ-2019-0037.R1>



# Secreted Trophic Factors of Mesenchymal Stem Cells Support Avascular Wound Recovery in A Patient with Vascular Occlusion: A Case Report

Ch'ng C.N<sup>1</sup>, Koh, K. Y<sup>1,2</sup>, Lim, W.K<sup>1,2</sup>



<sup>1</sup>Klinik de era, No. 3,5,7, Tingkat Taman Ipoh 12, Taman Ipoh Selatan, 31400 Ipoh, Perak Darul Ridzuan, Malaysia

<sup>2</sup>The Malaysian Society of Aesthetic Medicine (MSAM), Suite 313, Lot PO5A, Empire Shopping Gallery, Jalan SS 16/1, 47500 Subang Jaya, Selangor Darul Ehsan, Malaysia

## Abstract

**Introduction:** Stem cells secretome is a wide term for the complex group of chemicals produced by stem cells, including growth factors and cytokines. It promotes wound healing by its immunomodulatory properties, stimulating angiogenesis, accelerating skin re-epithelisation and improving extracellular matrix production modelling. This is the first report of hUC-MSCs (Human umbilical cord mesenchymal stem cells) secretome application in wound management in the case of vascular occlusion after filler injection.

**Case Presentation:** A 49 years old gentleman had sustained vascular occlusion from filler injection over the forehead for aesthetic purposes. He suffered from ulcers, pustules and hyperpigmentation over his forehead. His wound had healed well after multiple secretome injections over the course of 4 months.

**Conclusion:** The secretome of hUC-MSCs (Human umbilical cord mesenchymal stem cells) may be a potential therapeutic strategy for treating avascular wound.

**Keywords:** Platelet-Rich Plasma, PRP, Classification, Aesthetic

*Address of corresponding author: Klinik de era, No. 3,5,7, Tingkat Taman Ipoh 12, Taman Ipoh Selatan, 31400 Ipoh, Perak Darul Ridzuan, Malaysia*  
*Email:*  
*dr.chngcn@klinikdeera.com*

*Received: April 13, 2022*  
*Revision received: May 15, 2022*  
*Accepted after revision: May 23, 2022*  
*www.japa-edu.org*

The reconstruction of various cell types in the epidermal and dermal layers is a complex and well-orchestrated process during skin wound healing. In serious chronic conditions such as severe burns and diabetes, the wound healing process is delayed or fails, causing ulceration or other changes in the skin including abnormal skin structure or loss of structural functions. Hence, much effort was invested to develop novel and advanced therapeutic method such as platelet-rich plasma (PRP) therapy (Park et al., 2011), growth factor therapy (Penn et al., 2012), stem cell-based therapy (Lee et al., 2012), tissue engineering (Chen et al., 2009) and even gene therapy (Song et al., 2012). Among the aforementioned approaches, stem cell-based therapy has lately emerged as an appealing option for cutaneous wounds (Dulmovits & Herman, 2012) due to its therapeutic potential. However, despite the many promising outcomes, there are certain restrictions to consider in stem cell therapy. One of the major challenges, is the low survival rate and post administration fate of the cells following transplantation (Modo et al., 2002).

As technology in bioprocess and cell engineering advanced, stem cell secretome become an attractive option for cell-free therapy. Stem cells secretome is a wide term for the complex group of chemicals produced by stem cells, including growth factors, cytokines. The use of the stem cell secretome to treat severe cutaneous wounds could be a potential way to overcome the limits of viable replacement cell transplantation. A vast number of research on cardiovascular (Mirotsoy et al., 2011), liver (Kuo et al., 2008), and renal injuries have found direct evidence that the secretome plays an important role in encouraging regeneration (Cantaluppi et al., 2013). Similarly, stem cell-conditioned media, or alternatively named secretome has been used in a number of pre-clinical investigations as a viable option to replacement cell therapies for wound healing (Walter et al., 2010; Zhou et al.,

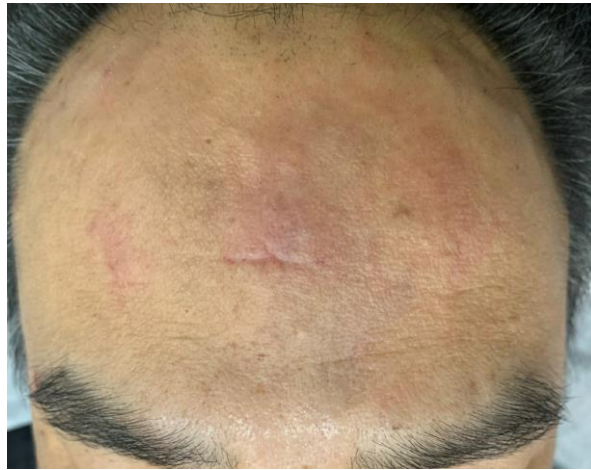2013; Chen et al., 2014; Jun et al., 2014). This has sparked interest in using the stem cell secretome to speed up the healing process in skin wounds.

It has been proposed that MSC-S (Mesenchymal Stem Cell Secretome) can contribute to wound healing via several mechanism. Firstly, it has immunomodulatory properties as MSC-S in vitro can inhibit activation and proliferation of immune cells including T cells, B cell, NK cells, neutrophils and macrophages. Secondly, MSC-S contains proangiogenic proteins such as angiopoietin-1, angiopoietin-2, granulocyte macrophages colony-stimulating factor, platelet-derived growth factor and others. These proteins can stimulate new vessels formation, leading to accelerated wound closure. Thirdly, growth factors in MSC-S can accelerate re-epithelisation due to its ability to enhance the dermal fibroblast and epidermal keratinocyte's migration and proliferation. Lastly, these growth factors can also stimulate collagen synthesis and accelerate new tissue formation. (Ahanger P et al., 2020).

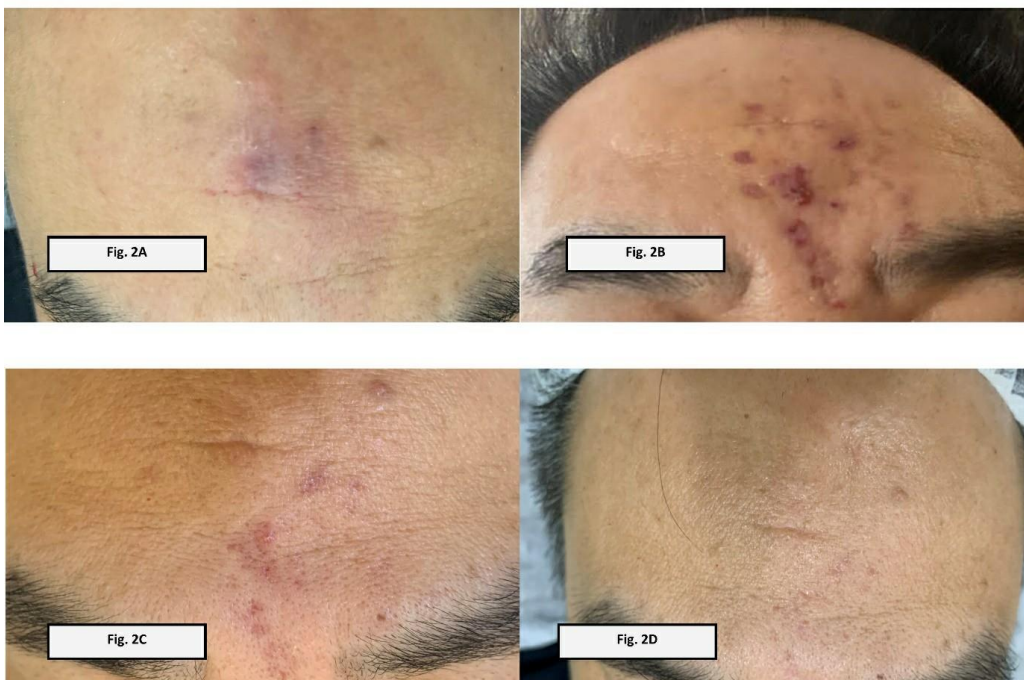
Here, we describe a work to evaluate the contribution of application of a MSC- Secretome for healing of filler induced avascular injury. As there are increasing demand to use filler as a method to improve appearance, vascular occlusion may be a complication after or during filler injection. Adverse event associated with vascular occlusion are pain, erythema, necrosis, scarring. Therefore wound management is important to improve patient outcome. We hope to explore further supporting treatment for wound healing after vascular occlusion other than the usual hyperbaric oxygen therapy (HBOT), Low molecular weight heparin and oral vasodilator.

### Case Presentation

Patient is a 49-year-old male with underlying Ischaemic Heart Disease, Dyslipidaemia and Hypertension with defaulted medication since



**Figure 1:**Photographic image, Day one (D1), after filler injection



**Fig. 2A.** Photographic image, Day two (D2) days, after Hyaluronidase correction.

**Fig. 2B.** Photographic image, Day seven (D7).

**Fig. 2C.** Photographic image, Day thirty-nine (D39).

**Fig. 2D.** Photographic image, Day one-hundred and twenty-two (D122).

March 2021. On 1<sup>st</sup> of July 2021, 0.35 ml of hyaluronic acid based injectable filler (Juvederm Volift, France) was injected on the sunken area at the subject's forehead for volumization. Within minutes, we noticed some grey hue over the left forehead extending to eyebrow, while capillary refill time (CRT) was about 2-3 seconds in certain part. No pain or discomfort was mentioned during the

procedure.

Approximately 300 IU of hyaluronidase (SRS International, Spain) was administrated all over the glabellar region and initial injection site respectively as management procedure. CRT then improved (< 2 seconds) over the forehead region.

Subject mentioned about slight discomfort

at the injection site, however no sign of inflammation or ulcers was detected 24 hours after procedure. Unfortunately, inflammation, pustules and new ulcers were observed at during subsequent monitoring over four days. Additional 500 IU of hyaluronidase (SRS International, Spain) were administrated at the redness region and glabellar region respectively. Upon further investigation, we found out that the subject punctured the pustules with unsterilized needle which may trigger the inflammation and adverse effect.

Widths and depths of the ulcers were recorded and photographed. We injected 2 ml of stem cells secretome for 3 consecutive days (Day 5, 6 and 7 Post injection respectively) with 25G cannula over the affected region in the subcutaneous layer. Upon completion of 3 days of IV antibiotics, he was then started on 5 days of T Unasyn 375mg BD.

Day 8 post injection, his wound had started to dry up with no new pustules/ulcers seen. Subject score 0 during pain scoring survey. We reviewed him again on Day 11 post injection, noted hyperpigmentation over forehead. There was no pain or new ulcers developed. We toned the hyperpigmented area with laser wavelength 1064nm (TRI-BEAM, Jeisys, Korea). Approximately 3 ml of stem cells secretome was administrated on the Day 11. On Day 12 post injection, we administrated another 1 ml of stem cells secretome and sprayed another 1 ml over the affected area.

During the subsequent follow up, 5 ml of stem cells secretome was injected at 1.5 months and 4 months after that incident. His wound had recovered well.

## Discussion

Avascular ulcer management is difficult because ulcers take a long time to heal, the therapy has a financial impact on patients and their families, and it is frustrating for patients. To address these issues, a variety of wound treatment techniques have been developed,

including the use of stem cell secretome, as described in this article.

The stem cell secretome increased the healing rate of chronic ulcers with little side effects or problems, according to our findings. Chronic ulcers can be caused by a variety of factors, including extended inflammatory conditions, high protease activity, and low growth factor levels. The secretome of stem cells contains a variety of paracrine substances, such as growth factors and cytokines (Vizoso et al., 2017).

The stem cells secretome may help to improve the wound microenvironment and so promote healing, especially during the inflammation phase of wound healing. Proinflammatory cytokines will treat any infection in the wound, while anti-inflammatory cytokines will lessen the inflammation process. Simultaneously, growth factors will aid wound healing by inducing angiogenesis and encouraging cell proliferation for the epithelialization process (Nuschke, 2014; Anandan et al., 2016; Park et al., 2017).

## Conclusion

The secretome of hUC-MSCs (Human umbilical cord mesenchymal stem cells) may be a potential therapeutic strategy for treating avascular wound. Further clinical studies are needed to prove treatment efficacy.

## Reference

1. Anandan, V., Jameela, W. A., Saraswathy, P., & Sarankumar, S. (2016). Platelet rich plasma: Efficacy in treating trophic ulcers in leprosy. *Journal of clinical and diagnostic research: JCDR*, 10(10), WC06.
2. Cantaluppi, V., Biancone, L., Quercia, A., Deregibus, M. C., Segoloni, G., & Camussi, G. (2013). Rationale of mesenchymal stem cell therapy in kidney injury. *American Journal of Kidney Diseases*, 61(2), 300-309.
3. Chen, L., Xu, Y., Zhao, J., Zhang, Z., Yang, R., Xie, J., ... & Qi, S. (2014). Conditioned



- medium from hypoxic bone marrow-derived mesenchymal stem cells enhances wound healing in mice. *PloS one*, 9(4), e96161.
4. Chen, M., Przyborowski, M., & Berthiaume, F. (2009). Stem cells for skin tissue engineering and wound healing. *Critical Reviews™ in Biomedical Engineering*, 37(4-5).
  5. Dulmovits, B. M., & Herman, I. M. (2012). Microvascular remodeling and wound healing: a role for pericytes. *The international journal of biochemistry & cell biology*, 44(11), 1800-1812.
  6. Jun, E. K., Zhang, Q., Yoon, B. S., Moon, J. H., Lee, G., Park, G., ... & You, S. (2014). Hypoxic conditioned medium from human amniotic fluid-derived mesenchymal stem cells accelerates skin wound healing through TGF- $\beta$ /SMAD2 and PI3K/Akt pathways. *International journal of molecular sciences*, 15(1), 605-628.
  7. Kuo, T. K., Hung, S. P., Chuang, C. H., Chen, C. T., Shih, Y. R. V., Fang, S. C. Y., ... & Lee, O. K. (2008). Stem cell therapy for liver disease: parameters governing the success of using bone marrow mesenchymal stem cells. *Gastroenterology*, 134(7), 2111-2121.
  8. Lee, S. H., Jin, S. Y., Song, J. S., Seo, K. K., & Cho, K. H. (2012). Paracrine effects of adipose-derived stem cells on keratinocytes and dermal fibroblasts. *Annals of Dermatology*, 24(2), 136-143.
  9. Mirotsov, M., Jayawardena, T. M., Schmeckpeper, J., Gneccchi, M., & Dzau, V. J. (2011). Paracrine mechanisms of stem cell reparative and regenerative actions in the heart. *Journal of molecular and cellular cardiology*, 50(2), 280- 289.
  10. Modo, M., Rezaie, P., Heuschling, P., Patel, S., Male, D. K., & Hodges, H. (2002). Transplantation of neural stem cells in a rat model of stroke: assessment of short-term graft survival and acute host immunological response. *Brain research*, 958(1), 70-82.
  11. Nuschke, A. (2014). Activity of mesenchymal stem cells in therapies for chronic skin wound healing. *Organogenesis*, 10(1), 29-37.
  12. Park, H. B., Yang, J. H., & Chung, K. H. (2011). Characterization of the cytokine profile of platelet rich plasma (PRP) and PRP-induced cell proliferation and migration: Upregulation of matrix metalloproteinase-1 and-9 in HaCaT cells. *The Korean journal of hematology*, 46(4), 265-273.
  13. Park, J. W., Hwang, S. R., & Yoon, I. S. (2017). Advanced growth factor delivery systems in wound management and skin regeneration. *Molecules*, 22(8), 1259.
  14. Penn, J. W., Grobbelaar, A. O., & Rolfe, K. J. (2012). The role of the TGF- $\beta$  family in wound healing, burns and scarring: a review. *International journal of burns and trauma*, 2(1), 18.
  15. Song, Seung-Hyun, et al. "Genetic modification of human adipose-derived stem cells for promoting wound healing." *Journal of Dermatological Science* 66.2 (2012): 98-107.
  16. Vizoso, F. J., Eiro, N., Cid, S., Schneider, J., & Perez-Fernandez, R. (2017). Mesenchymal stem cell secretome: toward cell-free therapeutic strategies in regenerative medicine. *International journal of molecular sciences*, 18(9), 1852.
  17. Walter, M. N., Wright, K. T., Fuller, H. R., MacNeil, S., & Johnson, W. E. B. (2010). Mesenchymal stem cell-conditioned medium accelerates skin wound healing: an in vitro study of fibroblast and keratinocyte scratch assays. *Experimental cell research*, 316(7), 1271-1281.

18. Zhou, B. R., Xu, Y., Guo, S. L., Xu, Y., Wang, Y., Zhu, F., ... & Luo, D. (2013). The effect of conditioned media of adipose-derived stem cells on wound healing after ablative fractional carbon dioxide laser resurfacing. *BioMed Research International*, 2013.
19. Ahangar, P.; Mills, S.J.; Cowin, A.J. Mesenchymal Stem Cell Secretome as an Emerging Cell-Free Alternative for Improving Wound Repair. *Int. J. Mol. Sci.* 2020, 21, 7038. <https://doi.org/10.3390/ijms2119703>



# Addressing Keloid and Hypertrophic Scars from Hair Transplant: A Case Report

Inderjit Kaur, MBBS, ABHRS<sup>1</sup>

---



<sup>1</sup>Klinik Dr Inder Petaling  
Jaya, Selangor, Malaysia

## Abstract

Hair transplants are significantly more effective in treating hair loss than non-surgical approaches such as over-the-counter medications, as it practically involves replacing old follicles with new follicles that are still able to grow real hair while delivering permanent results (Unger et al., 2011). Within four months, patients should anticipate between 10% and 80% of hair harvested from the donor area to regrow completely on the recipient site. However, it's critical to understand that different techniques may produce different results (Salanitri et al., 2009). In this paper, we will focus on some of the cases of patients who experienced unpredictable scarring of the donor area - in which the patients are not satisfied with the results due to the appearance of the keloid and hypertrophic scars. This caused discomfort among the patients as they strived for natural results and were not expecting to be left with such evident marks. Fortunately, these particular issues are addressed with a newer and less invasive technique of FUE and Scalp Micropigmentation (SMP).

**Keywords:** Follicular Unit Transplantation, Follicular Unit Excision, keloid, hypertrophic, FUE, Scalp Micropigmentation

*Address of corresponding  
author:*

*Klinik Dr Inder, P-G-022,  
Centrestage, Jalan 13/1,  
Seksyen 13, 46200 Petaling  
Jaya, Selangor, Malaysia  
Email:  
klinikdrinder@gmail.com*

*Received: March 26, 2022*

*Revision received: May  
10, 2022*

*Accepted after revision:  
May 20, 2022*

*www.japa-edu.org*

The Follicular Unit Transplantation (FUT), also known as Strip Surgery, involves collecting healthy hair follicles in a single session by removing a strip of hair from the back or sides of the scalp in a long, narrow strip, typically 20 to 25 cm in length and 1 cm to 2.5 cm in width. The doctor will then use staples or stitches to close the incision made in the donor area. Individual follicular units are then removed from the strip using stereo-microscopic dissection before restored into the balding area.

Unfortunately, some techniques of hair transplant may have its serious drawbacks, which is the linear scar found in the donor-occipital area, extending from the top of one ear to another (Ahmad, 2020). The scarring aftermath paves way for other techniques to overtake the older ones in providing a less invasive approach for hair restoration; one of them being the Follicular Unit Excision (FUE) (Rassman et al., 2002).

Normally, patients are informed beforehand of the inevitable scarring from the procedure, however, what is often left out is the fact that the scars can become unpredictable. This does not happen to every FUT patient but it is one of the risks of the procedure. In cases mentioned in this paper, two types of disfiguring scar may be formed (Alhamzawi, 2020) - keloid and hypertrophic scar - can be seen in the examples depicted in Figure 1.

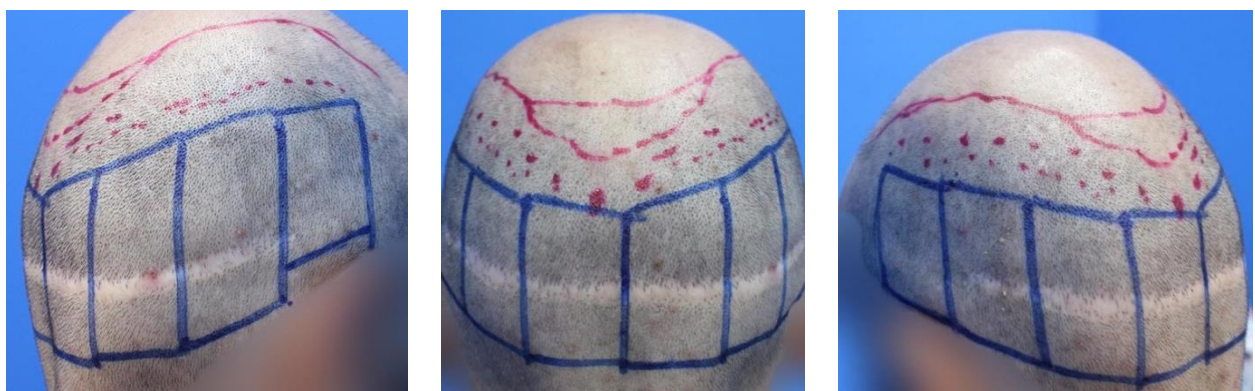These two scars are also known as raised scars and are abnormal responses to dermal injury, characterized by excessive collagen build-up (Brown et al., 1990). Keloids actually grow larger and project beyond the actual wound margins. Its size will not subside eventually (Garg et al., 2017). Any attempt to remove it would usually result in another formation of keloid scar as seen in Figure 2.

A hypertrophic scar has an appearance similar to keloid but is usually linear. The thickness of the scar tissue may restrict the amount of blood that reaches the newly grafted hair follicles, causing poor growth and defect (Pathomvanich, 2020).


In these cases, the scars are too visible and would cosmetically disfigure the patient's appearance (Garg & Garg, 2021). We have received cases of hair transplant patients from other clinics who are not happy with their scarring and wanted it covered. The problems are addressed with a corrective treatment using the FUE and SMP techniques and is covered in the following section.

### Case Presentation

first patient, a Malaysian man of Malay ethnicity, aged 42, suffering from androgenic alopecia, had undergone a FUT procedure six years prior to his first visit to our clinic. He started to lose his hair in his early-30s and had a hair transplant surgery to restore it. According



**Figure 3:** Linear scar from a hair transplant becomes more noticeable as it turns into a raised scar. Patients often are affected by this appearance and seek to conceal it.



**Figure 4:**Through FUE, scars can be repaired via hair restoration on scar tissue. For deep scars with uneven groove, autologous fat transfer procedure is performed by injecting fat into the scarred area to smoothen the surface.

to him, he was introduced to the procedure without any prior knowledge about other available forms of treatment, such as FUE. The outcome of the hair transplant was not satisfying as he started to go bald again on the front part after some time, on top of having a raised (keloid) scar on the donor site resulting from the procedure. This is especially problematic for the patient as he prefers having short hair where the scar will be most visible. Therefore, the patient resorts to wearing headgear and keeps his hair longer than he desires for this purpose; to reduce the visibility of his scar. The scar is more discernible in real life than in the photos provided in the next section.

The second patient, an Australian Caucasian man, aged 39, realized his progressive hair loss, and chose a FUT procedure to combat his problem. When asked if he had ever considered other procedures, he simply said that he based his choice on a recommendation by an acquaintance. The purpose of his visit to our clinic is also to get another hair transplant to increase his hair density and to be consulted on what can be done to reduce the visibility of his scar. Although initially yielding a satisfying result, he soon started to feel more insecure with the noticeable hypertrophic scar appearing at the back of his head. He received some comments from people

who pointed out the appearance, thus making him feel as if the result does not give a natural look, as he desired. Similar to the first patient, the scar is also too noticeable when the hair is too short or wet. When he goes for a swim or blows dry his hair, that's when the scar stands out the most. To cover up the scar, he also keeps his hair longer than he preferred so as to keep the scar more subtle, as can be seen in the photos.

## Methodology

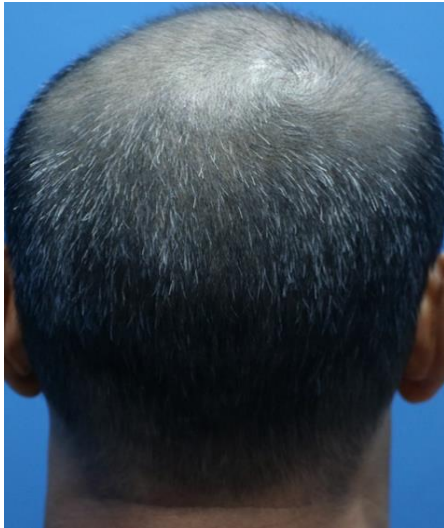### *Keloid Scarring*

The first patient's linear scar has turned into keloid (Figure 3 & Figure 4). Following the first hair transplant, he started to lose his hair again too and his purpose now is to treat the hair loss in addition to camouflaging the scar. During a hair restoration surgery, healthy hair grafts are harvested from the safe donor area and restored onto the new hairline (Figure 5). Patient requested some of the hair to be restored on the scarring site as well to conceal the mark left by the previous hair transplant, however, the patient was informed that hair on the scarred area will only have the survival rate of 60-70% (Figure 6).

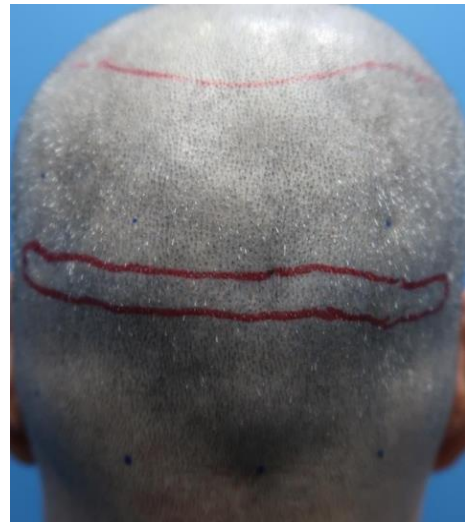### *Hypertrophic Scarring*

For the second case, a similar technique was applied to conceal the patient's hypertrophic scar from a previous hair transplant (Figure 7).

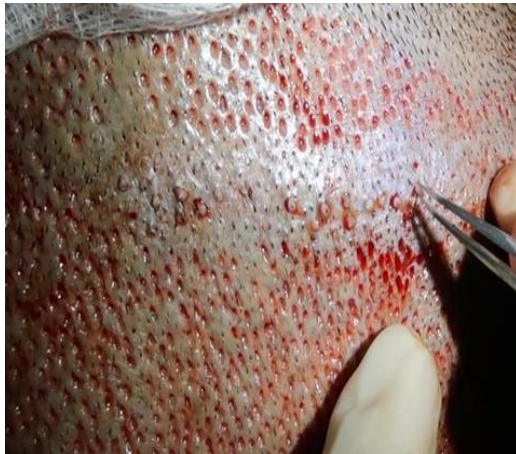



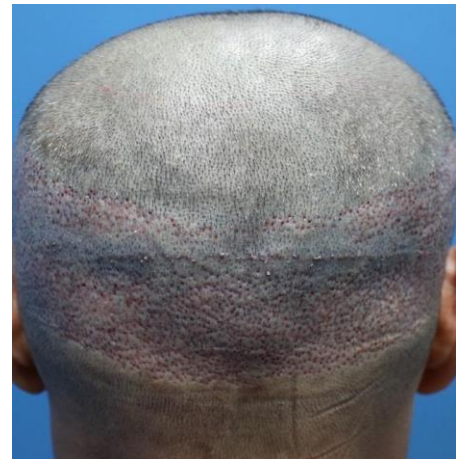**Figure 3:** Patient with keloid scar (before shaved)



**Figure 4:** Patient with keloid scar (after shaved)



**Figure 5:** Hair harvested from donor site



**Figure 6:** Hair grafts planted around the scar area

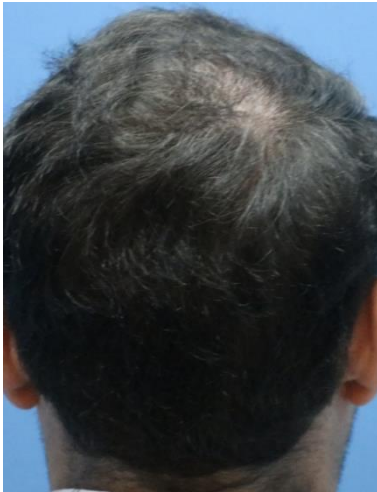The scar is more visible when his hair is short or wet. However, since the colour of the scar is significantly light, it could still be seen under the newly restored hair (Figure 8). Thus, the patient was advised to proceed with a Scalp Micropigmentation treatment directly on the scar as to further diminish its appearance, in addition to creating a fuller hair look (Figure 9).

### Result

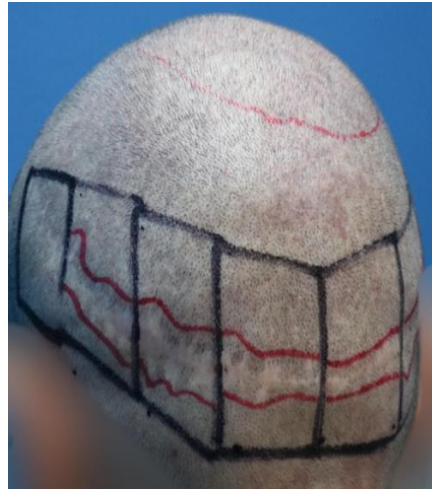After a few months, the patients returned for a follow-up. Due to a conflicting schedule, the patient with the keloid scar came in eight months later following his FUE procedure. The area around the keloid scar has been treated with

SMP to give the illusion of great hair density, reducing the appearance of the scar [Figure 10].

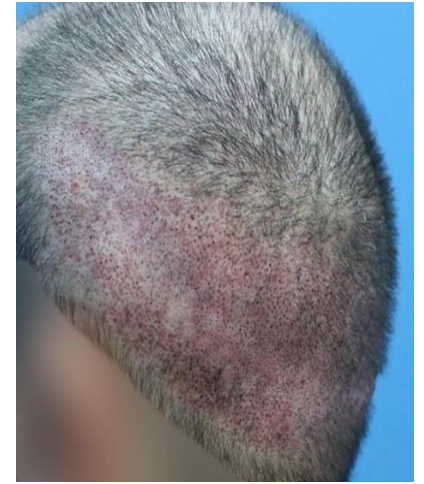As can be seen in [Figure 11], the second patient's hair has grown excellently, with a hair density great enough to completely cover up the hypertrophic area, complemented by the SMP pigment which helps in diminishing the appearance of the scar. It does so by camouflaging the light-coloured scar with darker pigment as an imitation of hair follicles.



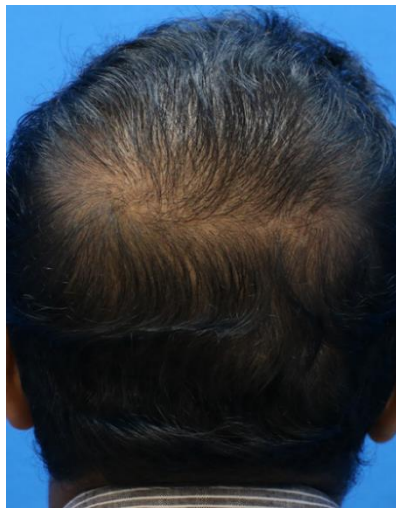**Figure 7:** Patient with hypertrophic scar (before shaved)



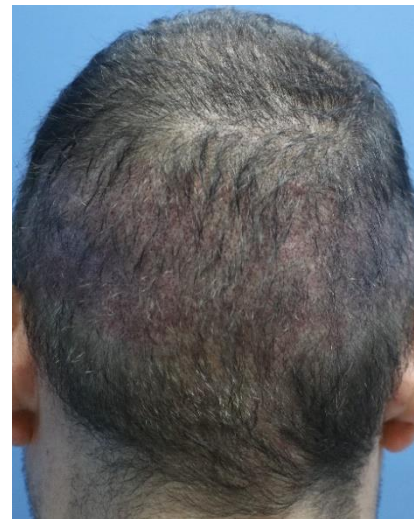**Figure 8:** Patient with hypertrophic scar (after shaved)



**Figure 9:** The comparatively lightened scar was camouflaged better with SMP (post-surgery)



**Figure 10:** Healthy hair growth in the previously balding area, and the keloid scar masked with SMP



**Figure 11:** Hypertrophic scar masked with the combination of FUE and SMP after 3 months

## Conclusion

What would constitute a good candidate to receive a FUE Hair restoration? The patient profiles for FUE are as listed down below:

1. Patients who wish to prevent a linear scar if they cut their hair extremely short.
2. Patients who have acceptable scarring from earlier surgery and are thus ineligible for strip excision.
3. Patients with insufficient scalp laxity to allow for strip harvesting.
4. Patients who heal with linear scars that are thicker or broad
5. Patients who require an immediate return to a high degree of activity following the surgery, such as athletes.
6. Patients who have a strong dislike for pain.
7. Patients with exceptionally broad hair shafts who require finer hair from the supra-auricular or low-neck areas to provide a more refined, attractive appearance.
8. Patients who require hair transplantation on the body

9. Patients with unsatisfactory cosmetic outcomes at the frontal hairline as a result of big grafts; FUE can be used to thin grafts one at a time.

Although similar in title, the two renowned methods of hair restoration can differ greatly. While some patients prefer to choose one of the two methods based on their preferences, others will have to act based on their specific circumstances.

To summarize the benefits and shortcomings of both treatments, it would be safe to deduce that FUE is the method for those who are more concerned with aesthetic dimensions of a chosen procedure; it is also an optimal treatment for one who wishes to wear their hair short. FUT, on the other hand, is the optimum procedure for those who deeply care about the quality of the results of their restoration and are not that much concerned with the outward appearance of their head after receiving the treatment.

## References

1. Ahmad, M. (2020). The battle begins: Is strip surgery really necessary? *Journal of Cosmetic Dermatology*, 19(11), 2990–2994. <https://doi.org/10.1111/jocd.13325>
2. Alhamzawi, N. K. (2020). Keloid scars arising after follicular unit extraction hair transplantation. *Journal of Cutaneous and Aesthetic Surgery*, 13(3), 237. [https://doi.org/10.4103/jcas.jcas\\_181\\_19](https://doi.org/10.4103/jcas.jcas_181_19)
3. Brown, M. D., Johnson, T., & Swanson, N. A. (1990). Extensive keloids following hair transplantation. *The Journal of Dermatologic Surgery and Oncology*, 16(9), 867–869. <https://doi.org/10.1111/j.1524-4725.1990.tb01575.x>
4. Garg, A. K., & Garg, S. (2021). Complications of hair transplant procedures—causes and management. *Indian Journal of Plastic Surgery*, 54(04), 477–482. <https://doi.org/10.1055/s-0041-1739255>
5. Garg, S., Kumar, A., Tuknayot, A., & Thami, G. P. (2017). Extensive donor site keloids in follicular unit extraction hair transplantation. *International Journal of Trichology*, 9(3), 127. [https://doi.org/10.4103/ijt.ijt\\_54\\_17](https://doi.org/10.4103/ijt.ijt_54_17)
6. Pathomvanich, D. (2020). Repairing widened fut donor scars. *International Society of Hair Restoration Surgery*, 30(4), 127–129. <https://doi.org/10.33589/30.4.127>
7. Rassman, W. R., Bernstein, R. M., McClellan, R., Jones, R., Worton, E., & Uyttendaele, H. (2002). Follicular unit extraction: Minimally invasive surgery for hair transplantation. *Dermatologic Surgery*, 28(8), 720–728. <https://doi.org/10.1046/j.1524-4725.2002.01320.x>
8. Salanitri, S., Gonçalves, A. J., Helene Jr., A., & Lopes, F. H. (2009). Surgical complications in hair transplantation: A series of 533 procedures. *Aesthetic Surgery Journal*, 29(1), 72–76. <https://doi.org/10.1016/j.asj.2008.11.005>
9. Unger, W., Shapiro, R., Unger, R., & Unger, M. (2011). *Hair transplantation* (5th ed., pp. 296). London: Informa Healthcare.



# Rhinophyma in Three Filipino Gentlemen which Showed Remarkable Improvement Using a Combination of Low Dose Oral Isotretinoin, Long Pulsed 1064-nm neodymium-yttrium-aluminum-garnet (Nd:YAG) Laser and Carbon Dioxide Laser

Johannes Flores Dayrit, MD<sup>1</sup> & Julius Garcia Gatmaitan, MD<sup>2</sup>



<sup>1</sup>De La Salle Medical and Health Sciences Institute & Research Institute for Tropical Medicine

<sup>2</sup>Gatmaitan Medical and Skin Center, Skines Aesthetic and Laser Center

## Abstract

We present three cases of rhinophyma in three Filipino gentlemen in terms of clinical, dermoscopy and histopathologic characteristics. All 3 patients were prescribed low dose oral isotretinoin with a combination of long pulsed 1064-nm neodymium-yttrium-aluminum-garnet (Nd:YAG) laser treatments. Two of the patients further underwent bulk ablation by carbon dioxide laser. A combination of low dose oral isotretinoin 0.3 mg/kg/day and long pulsed Nd-YAG 1064nm laser utilizing vascular and hair removal parameters resulted to a rapid remission and dramatic improvement after 6 months of treatment and after 6 months follow-up. This treatment combination is promising and has not yet been described in the literature.

**Keywords:** rosacea, rhinophyma, isotretinoin, laser

*Address of corresponding author:*

*De La Salle Medical and Health Sciences Institute & Research Institute for Tropical Medicine,  
Email:  
yohanmdderm@gmail.com*

*Received: 5 May 2022*

*Revision received: 19 May 2022*

*Accepted after revision: 25 May 2022*

*www.japa-edu.org*

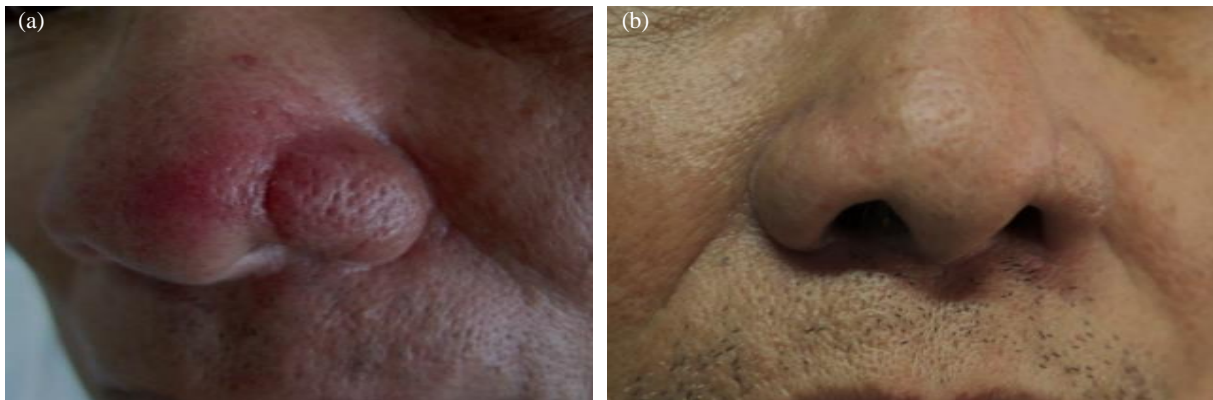
Rhinophyma is a subtype of rosacea with enlargement of the nose, prominent pores and nodular deformity. The condition is considered uncommon or underreported in Asians. Cosmetic deformity and social stigma are significant concerns of patients. Antibiotics and oral isotretinoin has been reported to induce remission in early stages. Ablative lasers and plastic surgery are treatment options for chronic and recalcitrant cases. (Powell, 2005)

### Case Presentation

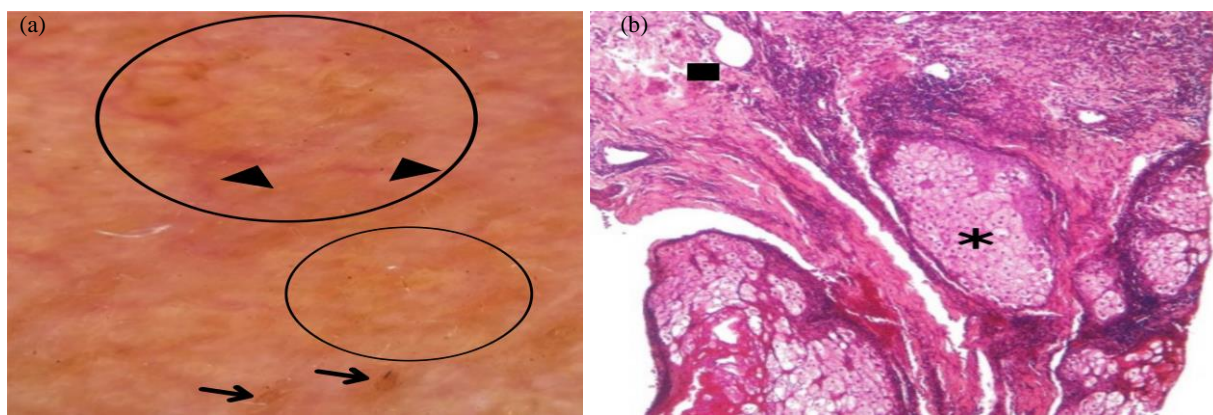
Case 1 is a 61-year-old male who presented with asymptomatic nasal erythema and progressive nose enlargement for 2 years. Physical examination revealed an erythematous plaque with enlarged pores on the left ala nasi which extends to the tip of the nose (Fig 1a). Dermoscopy revealed dilated pores, yellowish areas and curvilinear and serpentine vessels (Fig 2a). Histopathology revealed dilated blood vessels, sebaceous gland hypertrophy and a moderately dense periadnexal inflammatory infiltrate of lymphocytes. (Fig 2b) The diagnosis is moderate-grade rhinophyma because of the patulous follicles with contour change without nodule formation. Patient had baseline laboratory results (complete blood count, kidney function tests, liver function tests, and lipid profile tests) within normal range. The patient was started on oral isotretinoin at 0.25 mg/kg/day which lasted for 6 months. After 2 months of oral isotretinoin, the patient underwent first session of long pulsed 1064-nm Nd:YAG laser (Cutera®, Brisbane CA) using the following parameters: laser hair removal setting (fluence: 50 J/cm<sup>2</sup>, pulse duration: 20ms, repetition rate 0.9 Hz). On the 3<sup>rd</sup> month of oral isotretinoin, the settings were changed to long pulsed 1064-nm Nd:YAG laser (Cutera®, Brisbane CA) laser genesis setting (fluence: 8 J/cm<sup>2</sup>, spot size: 5mm, pulse duration: 0.3ms, repetition rate 10 Hz) for 5 more monthly sessions. The patient completed a total of 6 sessions of long pulsed 1064-nm Nd:YAG laser (Cutera®, Brisbane CA) session with 4 weeks

interval. The patient showed remarkable improvement after 6 months follow-up.

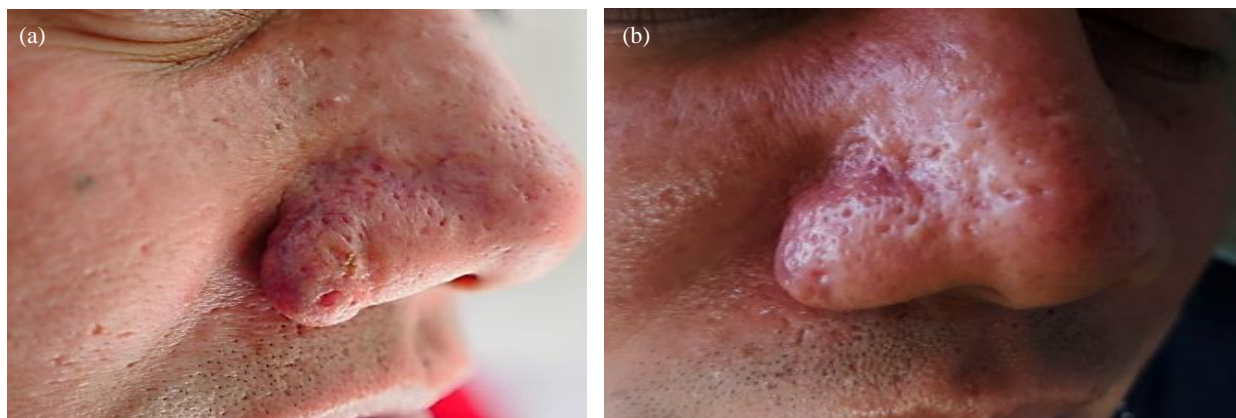
Case 2 is a 47-year-old male who was referred because of a red nodule on the right ala nasi for 4 years. On physical examination he presented with a 1.4 x 1.0 cm nodule with patulous follicles and surface telangiectasia. (Fig 3a) Dermoscopy revealed prominent pores, yellow areas and prominent linear blood vessel. (Fig 2a) Histopathology revealed prominent telangiectasia, sebaceous gland hypertrophy and a moderate periadnexal inflammatory infiltrate of lymphocytes. (Fig 2b) The patient was classified as having severe rhinophyma because of the presence of patulous follicles, contour change and the nodule formation. Patient had baseline laboratory results (complete blood count, kidney function tests, liver function tests, and lipid profile tests) within normal range. He was started on low dose oral isotretinoin at 0.20 mgs/kg/day. After 2 months of oral isotretinoin, the patient underwent first session of long pulsed 1064-nm Nd:YAG laser (Cutera®, Brisbane CA) using the following parameters: laser vascular setting (fluence: 130 J/cm<sup>2</sup>, spot size: 4mm, pulse duration: 20ms, repetition rate 0.0 Hz) to treat the prominent surface telangiectasia. Carbon dioxide laser (Smaxel, iDS, Korea) ablative resurfacing with the following parameters (fluence: 215mJ, 5ms pulse duration) was used to debulk the nodule. On the 3<sup>rd</sup> month of oral isotretinoin, the settings were changed to long pulsed 1064-nm Nd:YAG laser (Cutera®, Brisbane CA) laser hair removal setting (fluence: 50J/cm<sup>2</sup>, spot size: 10mm, pulse duration: 20ms, repetition rate 0.9Hz) for 5 more monthly sessions. The patient completed a total of 6 sessions of long-pulsed Nd:YAG 1064 laser session and 1 session of carbon dioxide laser bulk ablation with 4 weeks interval. Remarkable improvement was observed even after 6 months after discontinuation of oral isotretinoin. (Fig 3b).



**Figure 7:** Case 1- Erythematous plaque with enlarged pores on the left ala nasi which extends to the tip of the nose (a) remarkable improvement after 6 months (b)

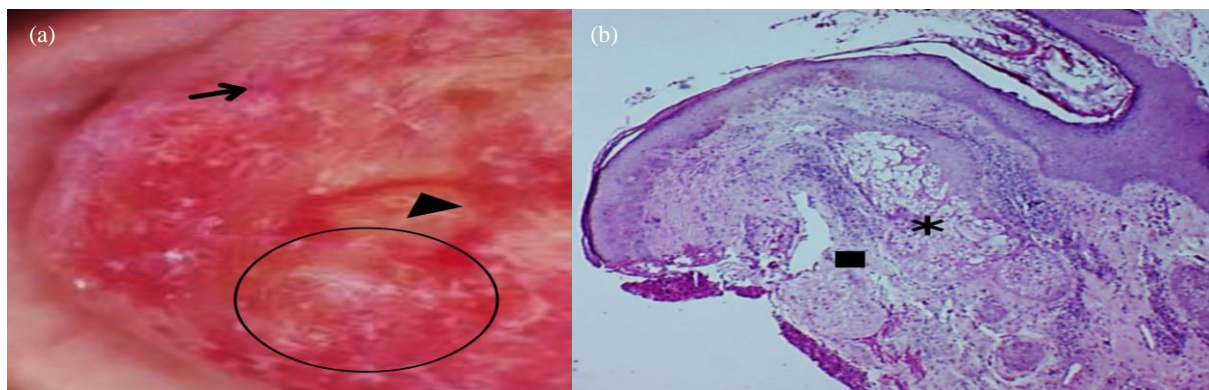


**Figure 7:** Case 1- Dilated pores (black arrow), yellowish areas (encircled area) and curvilinear and serpentine vessels (triangle). H&E shows dilated blood vessels (square), sebaceous gland hypertrophy (asterisk) and a moderately dense periadnexal inflammatory infiltrate of lymphocytes (a. DermLite DL4x10 ; b. H&E, 400x).

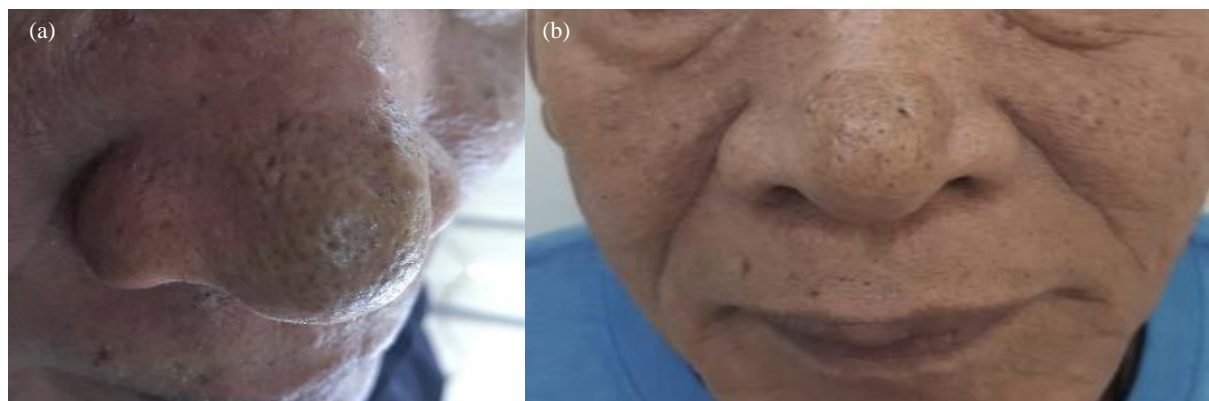


**Figure 7:** Case 2 - 1.4 x 1.0 cm nodule with patulous follicles and surface telangiectasia of four years duration (a) remarkable improvement after 6 months (b)

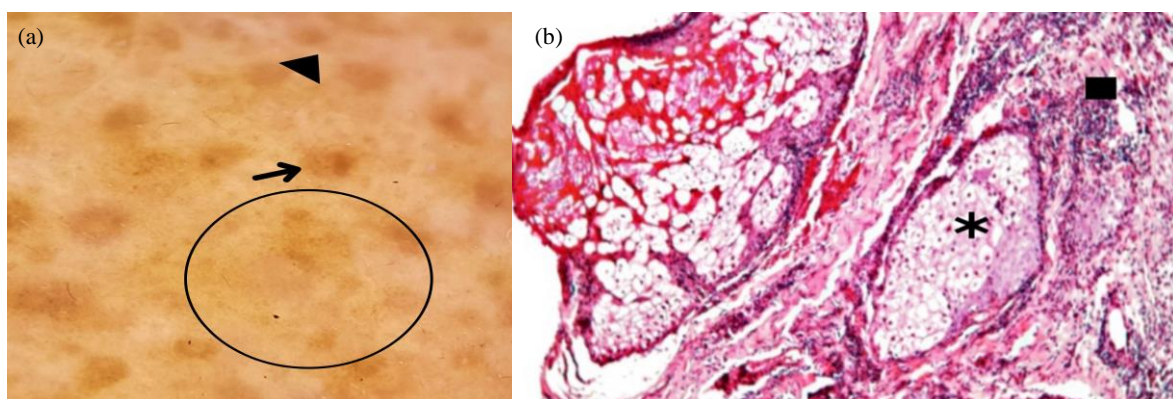




**Figure 10:** Case 2- Dilated pores (black arrow), yellowish areas (encircled area) and curvilinear and serpentine vessels (triangle). H&E shows dilated blood vessels (square), sebaceous gland hypertrophy (asterisk) and a moderately dense periadnexal inflammatory infiltrate of lymphocytes (a. Dermlite DL4x10 ; b. H&E, 400x).



**Figure 10:** Case 3- Erythematous plaque on the tip of the nose with prominent pores of three years duration (a) remarkable improvement after 6 months (b)



**Figure 10:** Case 3- prominent pores (black arrow), yellowish areas (encircled area) and white fibrotic areas with few blood vessels (triangle). H&E shows dilated blood vessels (square), sebaceous gland hypertrophy (asterisk) and a moderately dense periadnexal inflammatory infiltrate of lymphocytes (a. Dermlite DL4x10 ; b. H&E, 400x)

**Table 1:** Clinical characteristics of patients and laser settings

Case	Age	Sex	Number of Cutera long-pulsed Nd:YAG 1064 laser; Settings and Parameter	Number of Carbon Dioxide laser sessions; Settings and Parameter	Dose and duration of oral isotretinoin
1	61	M	6; <b>Laser hair removal setting</b> (fluence: 50 J/cm <sup>2</sup> , pulse duration: 20ms, repetition rate 0.9 Hz) for the first session and <b>laser genesis setting</b> (fluence: 8 J/cm <sup>2</sup> , spot size: 5mm, pulse duration: 0.3ms, repetition rate 10 Hz) for 5 more monthly sessions	None	0.25mg/kg/day for 6 months
2	47	M	6; <b>Laser vascular setting</b> (fluence: 130 J/cm <sup>2</sup> , spot size: 4mm, pulse duration: 20ms, repetition rate 0.0 Hz) for the first session and <b>laser hair removal setting</b> (fluence: 50J/cm <sup>2</sup> , spot size: 10mm, Pulse duration: 20ms, repetition rate 0.9Hz) for 5 more monthly sessions	1; Carbon dioxide laser <b>ablative resurfacing settings</b> (fluence: 215mj, 5ms pulse duration)	0.20mg/kg/day for 6 months
3	67	M	6; <b>Laser hair removal setting</b> (fluence: 50 J/cm <sup>2</sup> , pulse duration: 20ms, repetition rate 0.9) for first session and <b>laser genesis setting</b> (fluence: 8 J/cm <sup>2</sup> , spot size: 5mm, pulse duration: 0.3ms, repetition rate 10 Hz) for 5 more monthly sessions	1; Carbon dioxide laser <b>ablative resurfacing settings</b> (fluence: 215mj, 5ms pulse duration)	0.20mg/kg/day for 6 months

The last case is a 67-year-old man who presented with a bulbous nose for 3 years accompanied by occasional erythema and pruritus. On physical examination he presented with an erythematous plaque on the tip of the nose with prominent pores (Fig 5a). Dermoscopy showed prominent pores characterized by annular brown clods, yellowish areas, and white fibrotic areas with few blood vessels (Fig 6a). Histopathology showed enlarged sebaceous lobules with a

moderately dense periadnexal inflammatory infiltrate of lymphocytes (Fig 6b). This case was classified as severe grade rhinophyma because of the presence of patulous follicles with contour change, nodule formation and fibrosis. Patient had baseline laboratory results (complete blood count, kidney function tests, liver function tests, and lipid profile tests) within normal range. He was started on low dose oral isotretinoin (0.20 mg/kg/day). On his 2<sup>nd</sup> month of oral isotretinoin, the patient underwent first session of long pulsed 1064-nm Nd:YAG laser (Cutera®, Brisbane CA) using

the following parameters: laser hair removal setting (fluence: 50 J/cm<sup>2</sup>, pulse duration: 20ms, repetition rate 0.9). On his 3<sup>rd</sup> month of oral isotretinoin, Carbon dioxide laser (Smaxel, iDS, Korea) ablative resurfacing with the following parameters (fluence: 215mJ, 5ms pulse duration) was used to debulk the rhinophyma. The patient underwent 5 more sessions of long pulsed 1064-nm Nd:YAG laser (Cuteri®, Brisbane CA) laser genesis setting (fluence: 8 J/cm<sup>2</sup>, spot size: 5mm, pulse duration: 0.3ms, repetition rate 10 Hz) with 4 weeks interval. The patient completed a total of 6 sessions of long-pulsed Nd:YAG 1064 laser session and 1 session of carbon dioxide laser bulk ablation with 4 weeks interval. The patient showed remarkable improvement even after 6 months of treatment. (Fig 5b).

### Management And Outcome

Rhinophyma is a subtype of rosacea with enlargement of nose, prominent pores and nodular deformity. This condition is uncommon and underreported in Asians. Dermatologists should immediately recognize rhinophyma and institute immediate and proper intervention to prevent cosmetic disfigurement and social stigma.

In this case series, all patients were prescribed with mild cleanser, lightweight moisturizer sunscreen and low dose oral isotretinoin (0.2 to 0.3 mg/kg/day) for 6 months. To prolong the remission of this condition, all patients were treated with long pulsed Nd-YAG 1064nm and/or carbon dioxide laser ablative resurfacing. (Table 1).

### Discussion

Rhinophyma is one of the subtypes of glandular rosacea characterized by enlargement of the nose due to hyperplasia of sebaceous glands and connective tissue. It is associated with circumscribed nodular changes or diffuse thickening of the skin. The condition is seen predominantly in men. The thickening of the skin may occur with the other symptoms of

rosacea such as persistent centrofacial redness, edema, and presence of papules and pustules. This thickening of the skin and glandular hyperplasia may also involve the chin/jaw (gnatophyma), forehead (metophyma), ear (otophyma) or eyelid (blepharophyma). (Aloi, 2000)

Histopathological results of our study revealed prominent telangiectasia, sebaceous gland hypertrophy and a moderate periadnexal inflammatory infiltrate of lymphocytes. This is similar to the findings of Cribier, wherein phymatous rosacea is characterized by increased number of sebaceous glands and fibrosis of the dermis. There is enlargement of the follicular infundibula, surrounded by infiltrates mainly composed of lymphocytes and neutrophils. (Cribier, 2013).

In a study by Pelle et al., Doxycycline at 40 mg/day and low dose isotretinoin (0.3 mg/kg/day) are systemic treatment modalities for phyma which demonstrate a high level of evidence in systematic reviews. (Pelle, 2004). Isotretinoin significantly decreased nasal volume and diminished size and number of sebaceous glands in rhinophyma based on their study. (Pelle, 2004). The mechanism of action of isotretinoin is to decrease the size of the sebaceous glands and reduce sebum production. It also exerts an anti-inflammatory effect and immunomodulatory properties by down-regulating IL-2 or IFN- $\alpha$ . (Wilkin, 1994 & Erdogan, 1998).

Carbon dioxide laser and Erbium:YAG lasers are the primary ablative lasers used to treat rhinophyma. Both lasers show optimal cosmetic results and minimal scarring when used for resurfacing. (Goon, 2004). The use of long-pulsed Nd:YAG using hair removal and vascular parameters in combination with isotretinoin has not been reported yet in literature. The long-pulsed Nd:YAG using a fluence of 23-56 J/cm<sup>2</sup> is hypothesized to prolong remission in rhinophyma when laser treatments are done at monthly intervals.



Studies have demonstrated extensive necrosis of sebaceous glands 6 hrs after hair removal procedures and absence of hair and sebaceous glands after 3 months of treatment. (Bengini, 2001). Clinical endpoints for the hair removal and laser genesis setting which the researchers observed in this case series are mild erythema. For the vascular setting, vein color change and eventually disappearance.

Nowadays, the use of some lasers in patients currently taking isotretinoin is already considered safe. The retrospective study on 408 patients done by Andrade have demonstrated that laser therapy for hair reduction using the alexandrite, long pulsed Nd:YAG, Q-switched Nd:YAG and fractionated lasers is a safe option in patients on isotretinoin therapy. (Andrade, 2016). Furthermore, the systematic review conducted by Wootton and Williams on the association of oral isotretinoin and atypical wound healing in 380 patients revealed that the overall risk for scarring is small. (Wootton, 2014).

This case report highlights the efficacy and safety of low dose isotretinoin and the long pulsed Nd:YAG laser on rhinophyma in 3 Filipino patients. A larger case series or clinical trial is further recommended to validate these preliminary findings.

## References

1. Aloï, F., Tomasini, C., Soro, E., & Pippione, M. (2000). The clinicopathologic spectrum of rhinophyma. *Journal of the American Academy of Dermatology*, 42(3), 468–472. [https://doi.org/10.1016/s0190-9622\(00\)90220-2](https://doi.org/10.1016/s0190-9622(00)90220-2)
2. Andrade MP. (2016). Isotretinoin and lasers: Friends or foes. In *Journal of the American Academy of Dermatology*, Vol.74 Issue 5 Supplement 1 AB19. <https://doi.org/10.1016/j.jaad.2016.02.07>.
3. Bencini, P. L., Luci, A., Galimberti, M., & Ferranti, G. (1999). Long-term epilation with long-pulsed neodymium:YAG laser. *Dermatologic surgery: official publication for American Society for Dermatologic Surgery [et al.]*, 25(3), 175–178. <https://doi.org/10.1046/j.1524-4725.1999.08132.x>
4. Cribier B. (2013). Rosacea under the microscope: characteristic histological findings. *Journal of the European Academy of Dermatology and Venereology: JEADV*, 27(11), 1336–1343. <https://doi.org/10.1111/jdv.12121>
5. Erdogan, F. G., Yurtsever, P., Aksoy, D., & Eskioglu, F. (1998). Efficacy of low-dose isotretinoin in patients with treatment-resistant rosacea. *Archives of dermatology*, 134(7), 884–885. <https://doi.org/10.1001/archderm.134.7.884>
6. Goon, P. K., Dalal, M., & Peart, F. C. (2004). The gold standard for decortication of rhinophyma: combined erbium-YAG/CO<sub>2</sub> laser. *Aesthetic plastic surgery*, 28(6), 456–460. <https://doi.org/10.1007/s00266-004-0012-x>
7. Pelle, M. T., Crawford, G. H., & James, W. D. (2004). Rosacea: II. Therapy. *Journal of the American Academy of Dermatology*, 51(4), 499–514. <https://doi.org/10.1016/j.jaad.2004.03.033>
8. Powell F. C. (2005). Clinical practice. Rosacea. *The New England journal of medicine*, 352(8), 793–803. <https://doi.org/10.1056/NEJMc042829>
9. Wilkin J. K. (1994). Rosacea. Pathophysiology and treatment. *Archives of dermatology*, 130(3), 359–362. <https://doi.org/10.1001/archderm.130.3.359>
10. Wootton, C. I., Cartwright, R. P., Manning, P., & Williams, H. C. (2014). Should isotretinoin be stopped prior to surgery? A critically appraised topic. *The British journal of dermatology*, 170(2), 239–244. <https://doi.org/10.1111/bjd.127>

## A Nasal Dorsal Mucosal Cyst After Rhinoplasty: A Case Report

Umut Tuncel<sup>1</sup>



<sup>1</sup> Liv Samsun Hospital,  
Hançerli, Fatih Sultan  
Mehmet Cd No:155, 55020  
İlkadım/Samsun, Turkey

### Abstract

We attended a patient's case of dorsal nasal cyst that emerged after 5 years following a rhinoplasty surgery. The patient presented to our clinic with a mass in her nose, which had existed for at least 12 months prior to the clinic visit. After the cyst etiology was diagnosed, the patient was treated with cyst excision by open rhinoplasty. The etiology of nasal dorsal mucocoeles is unclear, however its development were able to be explained. Generally, two basic theories explain the nasal dorsal cysts which are the mucosal implantation or herniation. This case report aims to discuss on the management of the patient's nasal dorsal cysts especially in terms of disease's etiology.

**Keywords:** Nasal, dorsum, mucosal cyst, rhinoplasty.

*Address of corresponding  
author:*

*Liv Samsun Hospital,  
Hançerli, Fatih Sultan  
Mehmet Cd No:155, 55020  
İlkadım/Samsun, Turkey  
Email:  
drumuttuncel@gmail.com*

*Received: March 26, 2022  
Revision received: May  
10, 2022  
Accepted after revision:  
May 18, 2022  
www.japa-edu.org*

Nasal dorsal cysts can be detected as early or late onset. The early-onset cyst is generally caused by mucosal graft implantation during the surgery. Meanwhile the usual cause for the late-onset nasal dorsal cysts is defect in nasal bone or cartilaginous vault, which leads to mucosal herniation or migration. The dorsal nasal cyst is one of the rare complications after cosmetic rhinoplasty (Chang DY & Jin HR, 2008, Tracy LE & Badran K, 2014). Up to date only 26 cases of nasal dorsal cyst were documented in the literature (Aydogdu & Ozturk, 2015). Most of these cases were mucous-related with the most frequent localization is at the nasal dorsum. Other locations of nasal cysts were also reported such as at the nasal tip and medial canthal area (Giacomini PG, & Topazio D, 2014). Several circumstances were discussed in the etiology of the nasal dorsal cysts, in which common causes of the pathology are mucosal migration or ectopic free mucosal graft implantation during the surgery. In addition, foreign bodies, such as latex rubber fragments, have been stated as other cause of the cysts (Chang DY & Jin HR, 2008).

### Case Presentation

A 27-year-old female patient presented to our clinic with a 1-year history of slowly growing soft tissue mass at her nasal dorsum (Figure 1). Written consent was provided, by which the patient agreed to the use and analysis of her data. The patient had a cosmetic rhinoplasty 5 years ago. There was no infection or trauma after the surgery. During physical examination, an approximately 12×10 mm in sized, round, moderately mobile, semisolid, and painless soft tissue mass was detected on the midline of the nasal radix. Computed tomography (CT) scan demonstrated a nasal dorsal roof defect which include nasal bone and upper lateral cartilages (ULC) from radix to one top third of ULCs. In addition, a 16×14×10 mm sized low-density mass was found on the defected nasal bone extending towards ULC (Figure 2).

### Management And Outcome

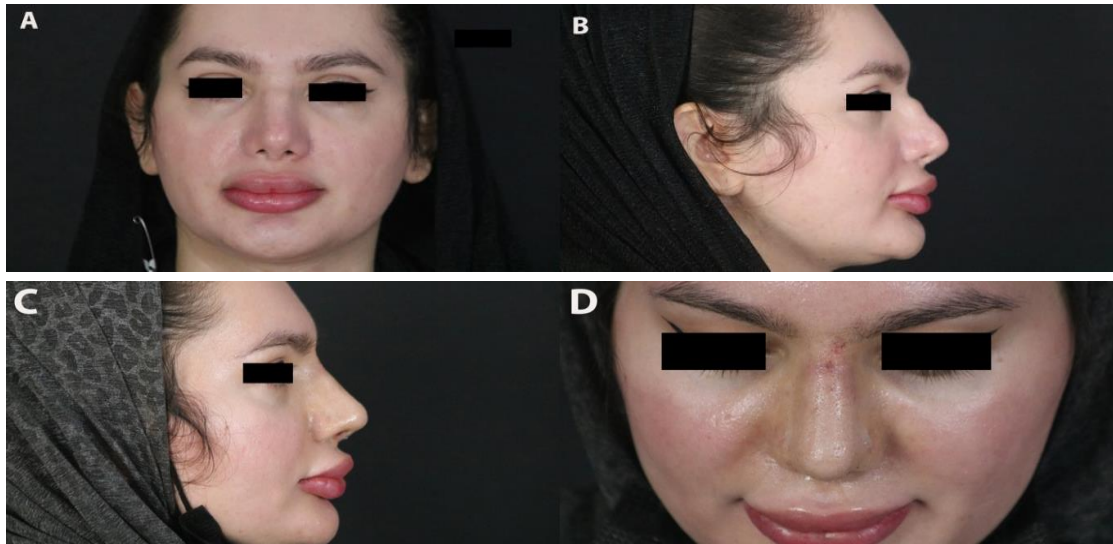Initially, when the patient presented at our clinic, we suspected the cause of the mucosal cyst may be due to the open nasal roof following a complication of previous rhinoplasty surgery. The patient was operated under general anesthesia employing an open rhinoplasty approach. In order to reach the cyst, the alar and ULC were supra-perichondrial dissected. During the dissection, we observed that the cyst comprises mucous with thin capsule within it (Figure 3). The capsule was removed after the light-yellow and viscous cyst content had been aspirated, in which the mucosal defect was then repaired with a 4/0 polydioxanone suture (PDS). After cleaning the surgical field with a 50-cc serum physiologic, the open roof was covered by shaping the costal cartilage transplant to resemble the dorsal aesthetic lines. PDS sutures were used to secure the costal cartilage transplant to ULC at two points. The nose was closed when all repairs were completed, and the cast was worn for one week. During this time, the patient was given antibiotics and anti-inflammatory medications.

During the follow up, the findings was uneventful, and a good aesthetic result was obtained.

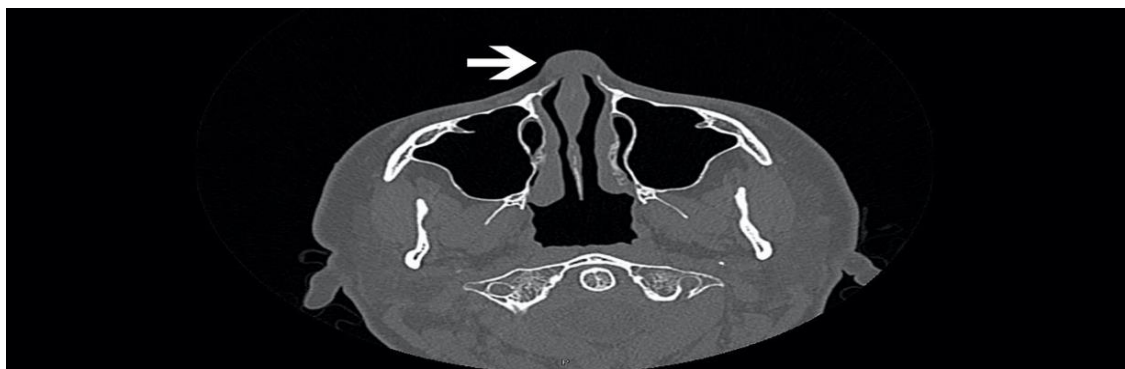
### Discussion

The etiology of nasal dorsal mucoceles is unclear, however, its development can be explained. Generally, two basic theories were commonly used to explain the nasal dorsal mucosal cysts which are mucosal implantation or herniation.

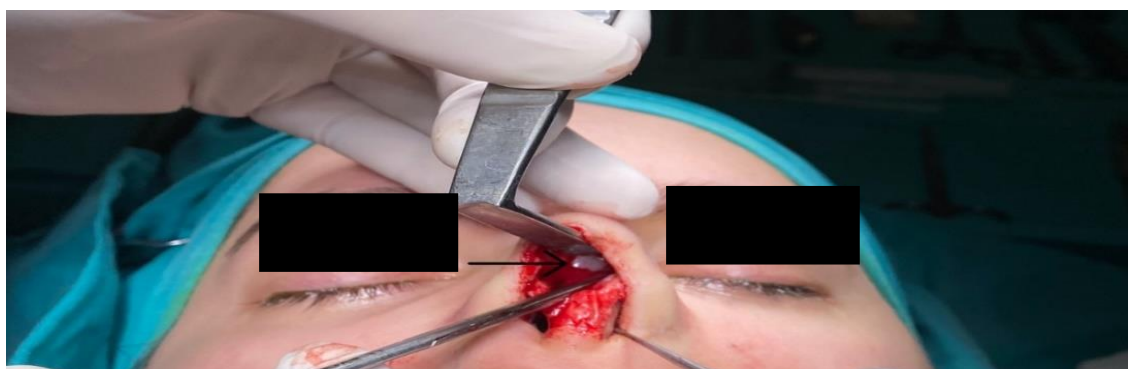
Surgery is commonly used treatment for a nasal dorsal mucocoele. The surgical approach usually differs according to the cyst etiology and the location of the cyst. In the presented case, the nasal dorsal defect following the previous rhinoplasty surgery was perceived to be the reason for the cyst development. It is believed an open roof may likely caused a mucosal herniation in the surgical excised field.



**Figure 11:** A 27-year-old female patient was presented to our clinic with a mass on her nasal dorsum. Pre-operative photographs (A: frontal view, B: lateral view) show around moderately mobile, semisolid, and painless soft tissue mass on the midline of the nasal radix. Photographs (C: lateral view, D: frontal view) were taken 1 month after surgery showing successfully removed nasal cyst with a good aesthetic result.



**Figure 2:** There was a nasal dorsal roof defect on the CT scan, including a low-density mass located on the defected nasal bone extending towards upper lateral cartilages (ULC). White arrow shows soft tissue mass on the nasal dorsum.



**Figure 12:** The cyst contained mucous material inside with a very thin capsule. Black arrow shows mucosal cyst on the nasal dorsum.

This may be caused through a mechanism like contact inhibition, which is a process that involves cell growth being blocked when cells

encounter each other. In other case reports, the intercartilaginous incisions or the defects at the osteotomy lines may also be responsible for the

nasal mucoceles. This is especially reported in the differential diagnosis related to the soft tissue lesions at the nasal radix or glabella which may include the encephalocele, dermoid or epidermoid inclusion cysts and also epidermal inclusion cysts or skin origin cysts. Following the surgical history and existing nasal dorsal defect, we consider the lesion presented by the patient as postsurgical nasal dorsal cysts. The pathologic examination was not required in our case since the cyst and specimen that were surgically removed are macroscopically diagnosable.

There are various surgical methods used in the literature. However, direct open and open or closed approach rhinoplasty are the most commonly used technique. Other ways can be thought of as different variations of these. The surgical method selected should generally be based on the etiology and location of the cysts. Since the nasal dorsal cysts was believed to be caused by an open roof secondary to the previous resection rhinoplasty, closing the roof using a rib graft next to the excision of the cyst was preferred as the approach to manage this case.

### Disclosures

The authors declared no potential conflicts of interest with respect to the research, authorship, and publication of this article. The informed consent form was taken from the patient.

### Funding

The authors received no financial support for the research, authorship, and publication of this article.

### References

1. Chang DY, Jin HR (2008). Foreign body inclusion cyst of the nasal radix after augmentation rhinoplasty. *J Korean Med Sci.* Dec;23(6):1109-12. doi: 10.3346/jkms.2008.23.6.1109.
2. Tracy LE, Badran K, Siaghani P, Wong BJ (2014). Dorsal nasal mucocele: a delayed complication of rhinoplasty. *Aesthetic Plast Surg.* Feb;38(1):100-103. doi: 10.1007/s00266-013-0233-y. Epub 2013 Nov 7. PMID: 24196012.
3. Aydoğdu İO, Öztürk N, Aksakal İA, Tuncel U (2015). A Rare Late Complication of Rhinoplasty: Dorsal Nasal Cyst. *Facial Plast Surg.* Oct;31(5):532-3. doi: 10.1055/s-0035-1564719.
4. Giacomini PG, Topazio D, Di Mauro R, Mocella S, Chimenti M, Di Girolamo S (2014). Unusual postrhinoplasty complication: nasal dorsum cyst. *Case Rep Otolaryngol.* 2014:617424. doi: 10.1155/2014/617424.