

Combination Treatment of Antibiotic, Retinoids and Chemical Peeling in Young Adult with Acne Scars: A Case Report

Vinushini A/P Chandra Sheaker¹, Reenisha Kaur A/P Sarjeet Singh², Nurul Dhiya Binti Hassannuddin³, Wirdatul Farah Binti Said⁴, Law Koon Lum^{5*}



¹Glojas Hair Transplant and Aesthetic Clinic, Kuala Lumpur

²Klinik Dr Inder, Selangor

³Hospital Rehabilitasi Cheras, Kuala Lumpur

⁴Hospital Seremban, Negeri Sembilan

⁵Clinic Tanjung Tokong, Pulau Pinang

Abstract

Acne vulgaris is a disorder of the pilosebaceous unit, which runs a chronic course and it is self-limiting. It is characterized by the presence of open and closed comedones, papules, pustules, and dermal tissue damage that eventually would cause hypertrophic scar formation. In the vast majority of cases, it is not until puberty that acne becomes a more significant problem. Acne often heralds the onset of puberty. In these young patients, the predominant lesions are comedones. Acne prevalence hits its peak during the middle-to-late teenage period, with more than 85% of adolescents affected, and then steadily decreases. However, acne may persist through the third decade or even later. The prevalence of high school students with moderate-to-severe acne was 19.9% in those students with a family history of acne and 9.8% in those students without a family history of acne. Acne in young adult male patient may start during adolescence and persist or have an onset in adulthood. Acne has various psychosocial effects that impact patients' quality of life. Treatments vary widely and treatment should be tailored specifically for each individual. In this paper, we will focus on the management and treatment options for young adult male patient with acne vulgaris.

Keywords: Acne Vulgaris, pilosebaceous unit, hypertrophic scar

Address of corresponding author:
Clinic Tanjung Tokong, 28-G-1,
The Bayu, Jalan Tanjung Tokong,
10470, Tanjung Tokong, Pulau
Pinang
Email: dr.lawkoonlum@gmail.com

Received: September 26, 2022

Revision received: November
12, 2022

Accepted after revision:

November 15, 2022

www.japa-edu.org

Acne vulgaris (AV) is a disease of the pilosebaceous unit that causes non-inflammatory lesions (open and closed comedones), inflammatory lesions (papules, pustules, and nodules), and varying degrees of scarring (1). While the course of acne may be self-limiting, the sequelae can be lifelong, with pitted or hypertrophic scar formation (2).

The four major pathogenic processes that lead to the formation of acne lesions are alteration of follicular keratinization that leads to comedones; increased and altered sebum production under androgen control; follicular colonization by *Cutibacterium acnes*; and complex inflammatory mechanisms that involve both innate and acquired immunity (3,4).

Treatment regime of patient's acne should be initiated early and be sufficiently aggressive to prevent permanent sequelae (2). Management of acne vulgaris in primary and specialist care includes advice on topical and oral treatments (including antibiotics and retinoids), treatment using physical modalities, and the impact of acne vulgaris on mental health and wellbeing (5).

Erythromycin and clindamycin are commonly used topical antibiotics for the treatment of acne. The development of *C. Acne* resistance towards antibiotics is less likely in patients who are treated with a combination of benzoyl peroxide/erythromycin or clindamycin. Therefore, the combination of these two products is preferable over monotherapy with topical antibiotics (2).

The tetracycline derivatives, doxycycline and minocycline, are commonly used in the treatment of acne. Although the oral administration of tetracyclines does not alter sebum production, it does decrease the concentration of free fatty acids and may take several weeks to become evident. Tetracycline may also act through direct suppression of the

number of *C. acnes*, but part of its action may be due to its anti-inflammatory activity (2).

The use of oral retinoid, isotretinoin, counteracts all the four pathophysiological factors. Although the mechanisms of isotretinoin that prolonged remission are not completely understood, it has been found that there is marked reduction in sebaceous gland activity and size other than altered follicular microclimate. Furthermore, there is also a reduction in toll-like receptor-2 (TLR2) expression on circulating mononuclear cells that is persistent for several months post-therapy of said mechanism. (2,6).

Chemical peeling is a skin resurfacing procedure commonly used for facial rejuvenation and aesthetics. It causes a manageable injury to the skin, thus resulting in subsequent regeneration of a new epidermal layer of the dermal tissues. The injury depth (superficial, moderate or deep) is determined by the concentration of acid used, and by the type of vehicle, buffering and duration of skin contact. Chemical peels have antibacterial, anti-inflammatory, keratolytic and comedolytic effects, and they can reduce sebum production. (7).

Case Presentation

22-year-old Chinese gentlemen, with no history of medical illnesses, presented to us with the complaint of recurrent acne lesions over his face, cheeks, chin and forehead for a more than a year. The patient has a habit of mechanically extracting pustular acne lesions and mechanically extracting comedonal lesions with his own fingers. Acne lesions have caused him psychological stress in his social life, as well as a decrease in his self-esteem. He is a graphic designer.

The patient has been experiencing work stress in recent weeks and will need to put in extra hours at night to meet his project deadlines and had previously sought numerous medical opinions for his acne lesions but stopped

receiving treatment after switching jobs a year ago. Upon performing an acne examination, numerous papular lesions, nodulocystic lesions, and white and black comedonal lesions were found over his forehead, cheeks, and U zone.

Clinically, he has acne vulgaris of moderate severity with grading of CASS 3 acne with predominantly papules and pustules lesion. Before the treatment begun, his blood investigation has taken as baseline prior to treatment. His result has showed normal liver enzymes of transaminases AST of 11 U/L, ALT of 23U/L and GGT 16 IU/L.

A variety of treatment regimens were suggested to him, including the use of oral and topical antibiotics, topical retinoids, chemical peeling, and oral retinoids. He has shown good response in the first two months of the 8-month treatment period following the oral and topical antibiotic combination. Following the start of low dose oral isotretinoid, a month of oral isotretinoin treatment revealed a significant improvement in his nodulocystic acne lesions.

Once his active lesions had lessened, chemical peeling was introduced to the patient. Trichloroacetic acid (TCA) 40% was applied with a moderate peeling depth until a light frosting was evident. Patient received a cooling and hydrating mask after each chemical peel to stop further skin erythema and inflammation.

In the following months, we used a combination of oral isotretinoid, chemical peeling, and sufficient skin hydration to control and prevent the recurrence of new acne lesions. After the duration of total 8 months of active treatment, he was advised to maintained on good healthy lifestyle, proper diet and regular follow up of his skin conditions.

Management an outcome

The patient was treated for 8 months using a combination of treatments. He was initially started on T.Minocycline 100mg daily for 8

weeks together with topical Zindaclin 1% twice daily to treat nodular and papular lesions on his cheeks, U zone, and T zone area. On top of that, he was advised to a proper skincare regime consisting of salicylic acid/benzoic acid cleanser and moisturizer.

After 8 weeks of oral minocycline 100mg OD treatment, there was a slight improvement where a reduction in papular lesions is seen. Subsequently, the patient was started on oral Isotretinoin 10 mg daily. He was advised to continue the application of the topical antibiotic treatment on the papular lesion.

On the 4 months of acne treatment, he underwent his first chemical peel session with Trichloroacetic acid (TCA) 40% to to reduce comedonal lesions, post-inflammatory hyperpigmentation and scarring due to acne. The results of TCA chemical peeling showed significant reduction in comedones and post-inflammatory hyperpigmentation.

For the upcoming subsequent months, the patient underwent another 3 sessions of a chemical peel with TCA 40% with 6 weeks interval of each chemical peelings. Overall, the patient noticed an improvement in his skin texture with no acne flare-ups and a reduced appearance of post-inflammatory hyperpigmentation.

He continued using topical retinoin once at night and topical zindaclin twice daily. Oral Isotretinoin was discontinued with total of 6 months durations and he was advised to continue topical retinoin 0.125% as maintenance.

Discussion

In this case study, a combination of topical antimicrobial and retinoid therapy as first-time therapy for acne vulgaris has come up with good outcome. Retinoids are comedolytic and have anti-inflammatory effects, whereas topical antibiotics have antimicrobial effects. Chemical peeling with Trichloroacetic acid (TCA) reduces

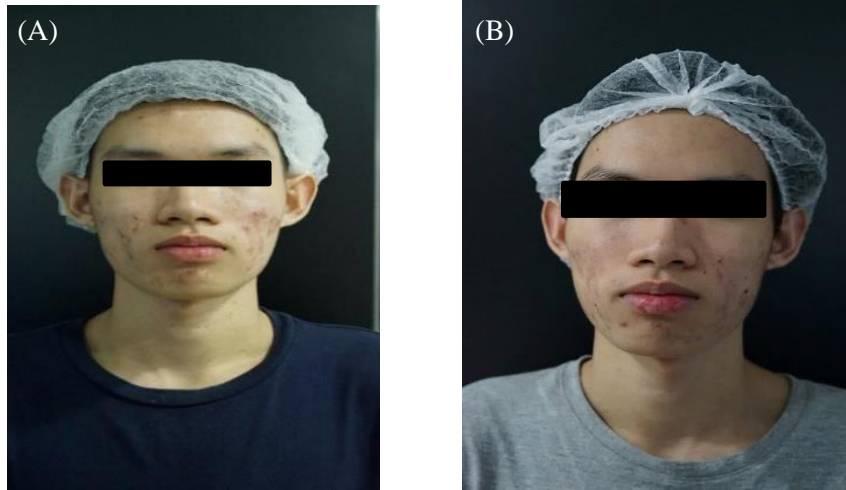

Figure 1. 22 years old gentleman with active skin lesions (A) Before treatment; (B) Slight reduction of papules and pustules after 8 weeks of oral antibiotics

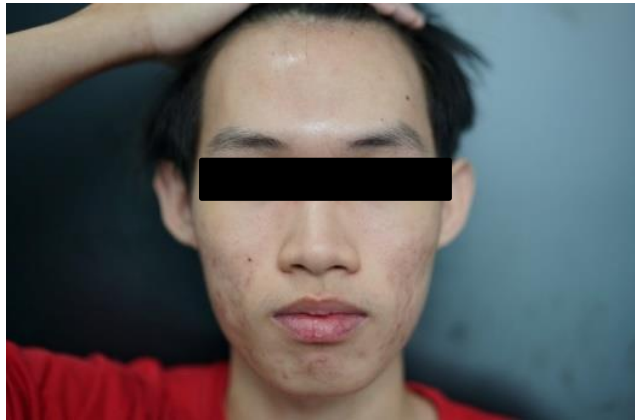

Figure 2. Marked reduction in active acne lesions after 1 months of oral isotretinoin

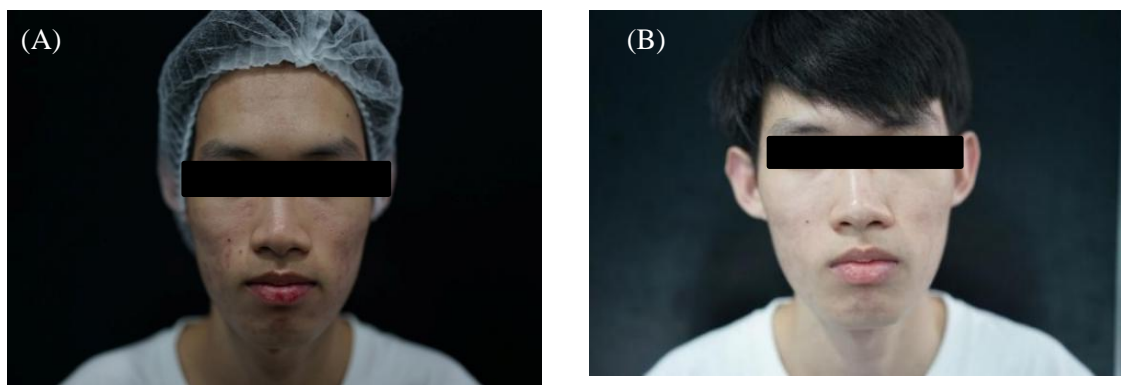


Figure 3. (A) Slight improvement of hyperpigmentation after 1 session of chemical peeling (B) Significant whitening of the skin after 4-5 sessions of chemical peeling

sebum production, less comedone and improves acne scar with increased collagenesis.

Topical antibiotics are mainly used for their role against *C. acnes*. They may also have anti-inflammatory properties. Topical antibiotics are not comedolytic, and bacterial resistance may develop to any of these agents. Commonly prescribed topical antibiotics for acne vulgaris include clindamycin, erythromycin, dapson and minocycline.

Topical retinoids are comedolytic and anti-inflammatory. They normalize follicular hyperproliferation and hyperkeratinization. Topical retinoids can continue as maintenance therapy to inhibit further microcomedone formation.

In this case, isotretinoin (systemic retinoid) also appears to be highly effective in the treatment of severe, recalcitrant acne vulgaris. Isotretinoin causes normalization of epidermal differentiation, depresses sebum excretion by 70%, is anti-inflammatory, and even reduces the presence of *Cutibacterium acnes*.

Trichloroacetic acid (TCA) 40% was used and the result was very satisfactory for patient in inducing long term remission of acne lesions and reducing scarring. TCA causes denaturation of epidermal and dermal proteins, destruction of dermal collagen, and coagulative necrosis of epidermal cells. The clinical effects are the result of dermal structure reorganization and increased collagen, glycosaminoglycans, and elastin in the dermis. TCA peels (15–50% concentrations) are available for the treatment of active acne. This peel self-neutralizes and has very low systemic absorption. Trichloroacetic acid (TCA) 40% peels are one of the low-cost mode of therapy for active acne vulgaris and associated scarring with no complications.

References

1. Bhate K., and Williams H.C. Epidemiology of Acne Vulgaris. *Br J Dermatol.* 2013;168(3):474-485. Retrieved from <https://pubmed.ncbi.nlm.nih.gov/23210645/>
2. Wolff K, Goldsmith L, Katz S, Gilchrist B, Paller AS, & Leffell D. *Fitzpatrick's Dermatology in General Medicine*, 8 th Edition. McGraw-Hill. 2011
3. Williams HC, Dellavalle RP, Garner S. Acne Vulgaris. *Lancet.* 2012;379(9813):314. Retrieved from <https://pubmed.ncbi.nlm.nih.gov/21880356/>
4. Sutaria A. H., Masood S., Schlessinger J. Acne Vulgaris. In: *StatPearls* (internet). Treasure Island (FL): StatPearls Publishing. 2022. Retrieved from <https://www.ncbi.nlm.nih.gov/books/NBK459173/>
5. National Institute for Health and Care Excellence. Acne Vulgaris: Management. London: NICE ;2021. NICE guideline NG198. Retrieved from <https://www.nice.org.uk/guidance/ng198>
6. Leyden J. J., Rosso J. Q. D., Baum E. W. The Use of Isotretinoin in the Treatment of Acne Vulgaris. *J Chin Aesthet Dermatol.* 2014 ;7 (2 Suppl): S3-S21. Retrieved from <https://www.ncbi.nlm.nih.gov/pmc/articles/PMC3970835/>
7. Chen, X., Wang, S., Yang, M., & Li, L. (2018). Chemical peels for acne vulgaris: a systematic review of randomised controlled trials. *BMJ open*, 8(4), e019607. Retrieved from <https://doi.org/10.1136/bmjopen-2017-019607>
8. Andrea L. Zaenglein, Arun L. Pathy, Bethanee J. Schlosser (2016). Guidelines of care for the management of acne vulgaris, Published 2016. Retrieved from <https://doi.org/10.1016/j.jaad.2015.12.037>
9. Georgios, Kontochristopoulos, Eftychia Platsidaki, 2017, Elsevier, Chemical peels in active acne and acne scars, retrieved from <https://doi.org/10.1016/j.clindermatol.2016.10.011>
10. Kaufman BP, Aman T, Alexis AF. Postinflammatory hyperpigmentation: epidemiology, clinical presentation, pathogenesis and treatment. *Am J Clin Dermatol.* 2018;19(4):489–503.

11. Han G, Armstrong AW, Desai SR, Guenin E. Novel tretinoin 0.05% lotion for the once-daily treatment of moderate-to-severe acne vulgaris in an Asian population. *J Drugs Dermatol*. 2019;18(9):910–6.
12. Tam C, Khong J, Tam K, Vasilev R, Wu W, Hazany S. A Comprehensive Review of Non-Energy- Based Treatments for Atrophic Acne Scarring. *Clin Cosmet Investig Dermatol*. 2022 Mar 14; 15:455-469. doi: 10.2147/CCID. S350040. PMID: 35359828; PMCID: PMC8963193.
13. Leyden J, Stein-Gold L, Weiss J. Why topical retinoids are mainstay of therapy for acne. *Dermatol Ther (Heidelb)*. 2017;7(3):293–304.
14. Zaenglein AL, Pathy AL, Schlosser BJ, Alikhan A, Baldwin HE, Berson DS, et al. Guidelines of care for the management of acne vulgaris. *J Am Acad Dermatol*. 2016;74(5):945–73 e33.