

## Therapeutic Efficacy of RuVY Touch (Ruby-like Versatile YAG) Q-Switched 660nm Wavelength Treatment on Ephelides (Freckles): A Case Report

Cheah Phei Chuin<sup>1\*</sup>, Chang Hui Xian<sup>2</sup>, Kee Ming Yao<sup>3</sup>, Lim Vivian<sup>4</sup>, Ng Poh Ling<sup>5</sup>



<sup>1</sup>UR Klinik Greenlane, Greenlane, Penang, Malaysia.

<sup>2</sup>UR Klinik Raja Uda, Butterworth, Penang, Malaysia.

<sup>3</sup>UR Klinik Bukit Mertajam, Bukit Mertajam, Penang, Malaysia.

<sup>4</sup>UR Klinik Puchong Outlet, Wilayah Persekutuan Kuala Lumpur, Malaysia.

<sup>5</sup>UR Klinik Cheras Leisure Mall, Wilayah Persekutuan Kuala Lumpur, Malaysia.

### Abstract

Ephelides is a common pigmentation characteristic observed in both Asians and Caucasians which has become a concerning cosmetic problem. We herein present a case of 24 years old Fitzpatrick type III gentleman with more than 10 years of ephelides receiving 8 sessions of Q-switched RuVY Touch 660nm wavelength without additional topical or oral medicine.

RuVY Touch treatment has a relatively weaker absorption rate by hemoglobin, lower the risk of vascular damage and associated post-inflammatory dyspigmentation. However, the absorption in melanin is still high, although slightly lower absorption compared with the 532nm beam. Hence, the safety level for treatment of discrete epidermal lesions is increased, which means faster healing and less unsightly erythema and crusting, which is an advantage for the patient.

In conclusion, our data suggest that RuVY Touch treatment, utilizing a converted wavelength of 660 nm, can be effectively used for the treatment for ephelides- freckles.

**Keywords:** Ephelides, freckles, Q-switched RuVY, laser

*Address of corresponding author:*

*UR Klinik Greenlane, 1A, Jalan*

*Delima, Island Glades, 11700*

*Greenlane, Penang, Malaysia.*

*Email: cherylcheah88@gmail.com*

*Received: September 26, 2022*

*Revision received: October 3, 2022*

*Accepted after revision: October 3, 2022*

*www.japa-edu.org*

Freckles, the lay term for ephelides, is a common pigmentation characteristic which is known as superficial benign pigment spots observed both in Asians and Caucasians. Superficial pigmentation includes freckles, solar lentigines and brown birthmarks are becoming a concerning cosmetic problem.

Ephelides often appear as small, pigmented spots (~1–2 mm, but can be larger), red to light brown in color, in fair-skinned and/or red-haired individuals and usually first appear at the age of 2–3 yr, then increase during adolescence and often partially disappear with age (1). This suggests ephelides are generally genetically determined, also induced or aggravated by ultraviolet (UV) light (2) in a chronically sun-exposed skin.

Mentioned in Zhang et al., 2004<sup>3</sup>, freckles are considered cosmetic disfigurements in Asia population, whereas in Western culture, freckles are considered fashionable. Many techniques and modalities have been described and used for the treatment of ephelides. For example, laser surgery/ light therapy, cryotherapy, topical or chemical peeling preparations.

In the 90's, popular methods of treatment or removal was superficial ablation, especially by light electrodesiccation, cautery or application of solid carbon dioxide or liquid nitrogen (4). However, these methods cause scarring and damage to the normal tissue. As the advancement in the dermatology field, melanin specific selective photothermolysis using Q-switched Ruby laser was introduced in 90's. Fast forward 30 years later, RUVY Touch (Ruby like Versatile YAG) Q-Switched 660nm wavelength has been widely practised in the treatment of superficial pigmentation.

In this case report, we will be focusing on light therapy treatment on ephelides, reporting the efficacy of RUVY Touch (Ruby like Versatile YAG) Q-Switched 660nm wavelength treatment on ephelides.

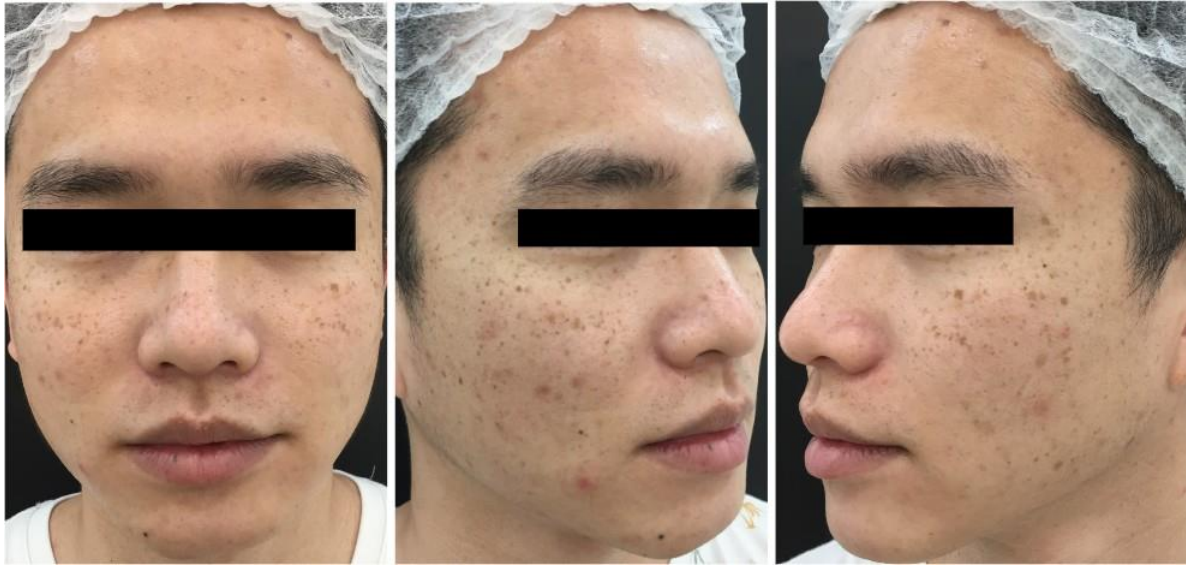## Case Presentation

A 24-year-old Chinese gentleman, Fitzpatrick type III with no known medical illness was presented to our clinic with pigmentations over bilateral cheeks and nose for 10 years prior to his visit to our clinic. He claimed that the pigmentations got worse after he started working as a salesman. He is actively involved in outdoor activities and basketball sports during his leisure time. Both his father and sister also have had similar pigmentation problems since young. Previously he has never undergone any depigmentation treatment before this. He felt insecure and low self-esteem with the noticeable pigmentations, as he received many comments at work who pointed out the appearance. He felt the customers will focus on his pigmentations rather than his work performance which affects his confidence. On physical examination, there are multiple light brown, small spots, round in shapes, covering bilateral cheeks, nose and forehead. He was diagnosed with ephelides or better known as freckles.

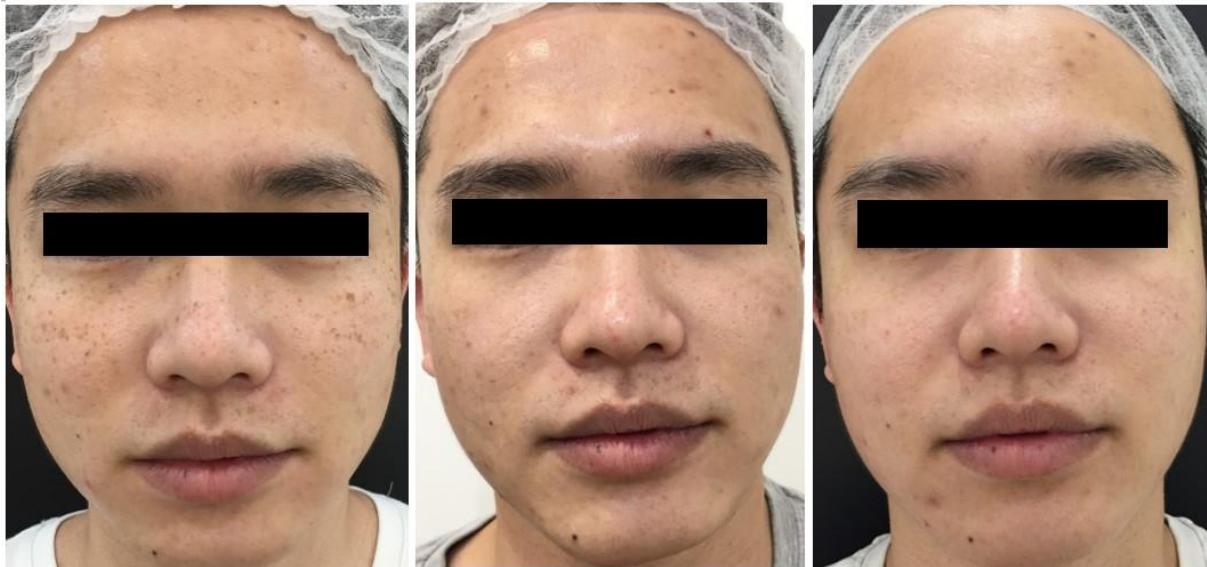
## Management And Outcome

This patient was started on depigmentation treatment in our clinic using Lutronic RuVY Touch Q-switched 660nm wavelength without any additional topical or oral medicine. He was treated with 1-2 passes and adjusted depending on the skin reaction. The end point of RuVY Touch Q-switched 660nm wavelength is whitening, hence the fluency is thus adjusted depending on the reaction. Patient also received Nd: YAG Q-Switched low-fluenced 1064nm laser treatment while undergoing RuVY treatment.

Customer is very satisfied with the overall results of his pigmentations with the global aesthetic improvement scale (GAIS) score of 1 (very much improved, optimal cosmetic results) and continues the treatment to obtain further improvement.



**Figure 1:** Front, right face (45 degree) and left face (45 degree) view photos of patient during the first presentation. Noted that there are multiple freckles over bilateral cheeks, nose and forehead.



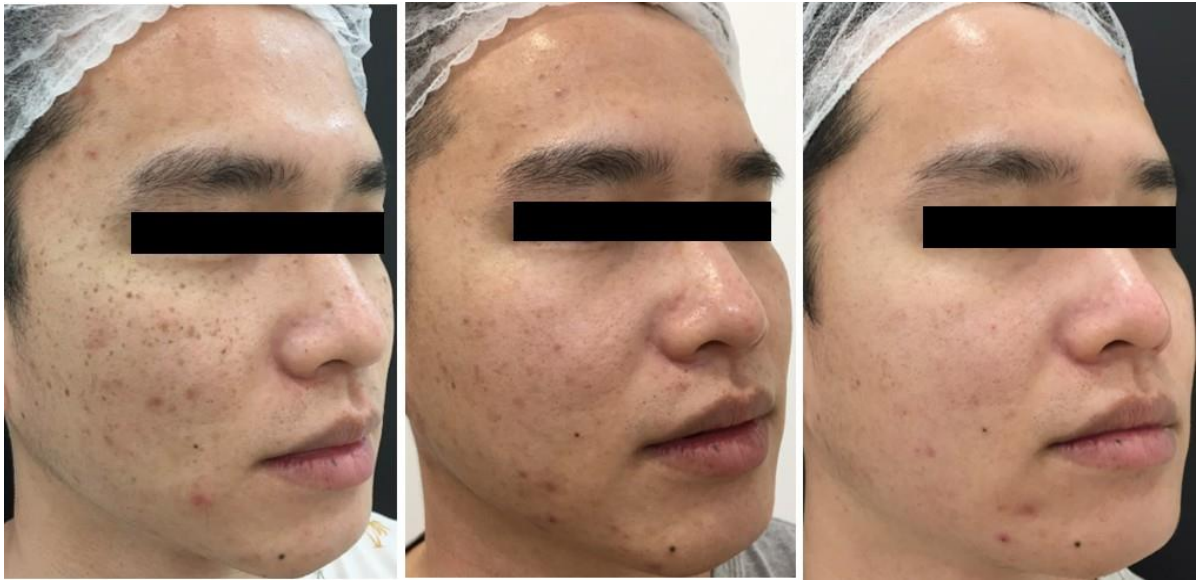**Figure 2:** Front view photos of first (left), fourth (center) and eighth (right) treatment. Noted that there is significant improvement of the freckles on whole face.

### Discussion

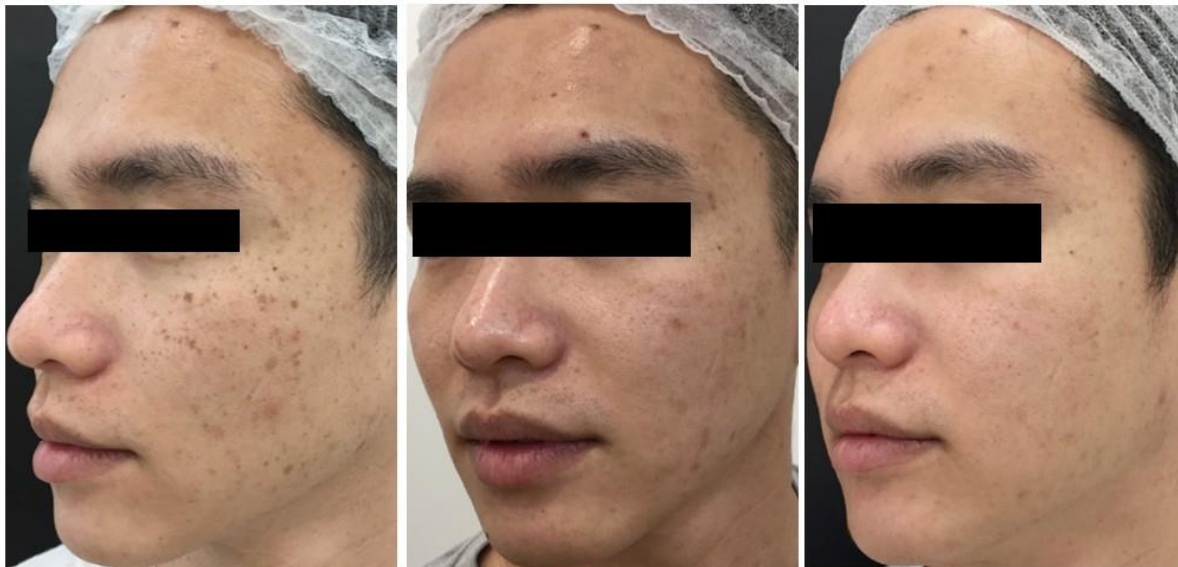Q-switched (QS) lasers are widely used to effectively treat a variety of cutaneous pigmentation lesions by targeting pigments via non-ablative selective photo-thermolysis. Melanin absorption is higher in QS 532-nm neodymium-doped yttrium aluminum garnet (Nd:YAG) laser treatment than other QS laser treatments; however, better absorption rates to target tissues are not always associated with

better clinical outcomes. For example, higher absorption by hemoglobin of QS Nd:YAG laser energy at 532 nm significantly increases the risk of unexpected side effects, in particular damage to superficial vessels. Additionally, Asian patients of darker skin type with higher amounts of melanin are at higher risk of post-laser therapy hyperpigmentation and erythema.





**Figure 3:** Right face (45 degree) view photos of first (left), fourth (center) and eighth (right) treatment. Noted that there is significant improvement of the freckles on right side of face.



**Figure 4:** Left face (45 degree) view photos of first (left), fourth (center) and eighth (right) treatment. Noted that there is significant improvement of the freckles on left side of face.

Although QS 532- and 1,064-nm Nd:YAG lasers are still the most widely used devices for treating various pigmentation disorders, QS ruby lasers with a wavelength of 694 nm have been shown to facilitate better absorption by melanin than QS 1,064-nm Nd:YAG lasers and weaker absorption by hemoglobin than 532-nm lasers. Reportedly, QS ruby lasers have proven successful in tattoo removal and in treating cutaneous pigmentations lesions, including melasma,

freckles, lentigines, café-au-lait macules, Becker's nevus, and nevus of Ota. Using a handpiece equipped with solid dye, 532-nm QS Nd:YAG laser energy can be converted to 660-nm laser energy for use in ruby-like versatile YAG (RuVY) laser treatment.

In this study, we attempted to demonstrate the clinical efficacy of RuVY treatment on ephelides-freckles. RuVY treatment was performed by converting 532-nm QS Nd:YAG laser energy to 660nm laser

**Table 1:** Parameters used during each session of treatment.

Session	Date	Mode	Fluence (J/cm <sup>2</sup> )	Frequency (Hz)
1	6/10/20	RuVY Q-switched 660nm	0.75	1
2	4/11/20	RuVY Q-switched 660nm	0.80	1
3	2/12/20	RuVY Q-switched 660nm	0.75	1
4	16/3/21	RuVY Q-switched 660nm	0.80	1
5	13/4/21	RuVY Q-switched 660nm	0.80	1
6	23/6/21	RuVY Q-switched 660nm	0.85	1
7	14/7/21	RuVY Q-switched 660nm	0.85	1
8	11/5/22	RuVY Q-switched 660nm	0.85	1

energy. Although QS lasers are preferred and widely used for the treatment of epidermal and dermal pigmented disorders, a shorter pulse duration can result in post-therapy hyper- or hypopigmentation due to higher risk of unwanted photomechanical effects on adjacent tissue components, especially blood vessels. As with QS ruby lasers with a wavelength of 694-nm, the wavelength-converted 660-nm laser, which is a quite similar but not identical to 694-nm lasers, was theoretically expected to offer better absorption by melanin and weaker absorption by hemoglobin.

This patient was treated with 8 sessions of RuVY treatment using a QS Nd:YAG laser device (SPECTRA XTMM, Lutronic Corporation, Goyang, Korea). A handpiece equipped with solid dye was used to convert 532-nm wavelength laser energy to 660-nm wavelength laser energy. At each RuVY treatment session, a single or two passes were made with the device using the settings of a 660-nm wavelength, a pulse energy of 0.75-0.85 J/cm<sup>2</sup>, a frequency 1Hz, and a 3-mm spot size. As RuVY treatment involves delivery of laser energy over a small spot size of 2-3 mm and has

a wavelength of 660 nm for relatively weaker absorption rate by hemoglobin, the risk of vascular damage and associated post-inflammatory dyspigmentation is potentially low. The absorption in melanin is still high, but with slightly lower absorption compared with the 532nm beam, the safety level for treatment of discrete epidermal lesions is increased. The 660nm RuVY Touch can deliver intense energy onto the same spot size compared with 532nm and can precisely treat only the lesion; unnecessary heat damage to the surrounding areas is therefore contained as the undesired laser energy is not delivered. Accordingly, the skin reaction is comparatively milder after RuVY Touch treatment, which means faster healing and less unsightly erythema and crusting, which is an advantage for the patient.

In conclusion, our data suggest that RuVY treatment, utilizing a converted wavelength of 660 nm, can be effectively used for the treatment for ephelides- freckles.

## Reference

1. Plensdorf, S., and Martinez, J. Common pigmentation disorders. *Am. Fam. Physician.* 2009; 79, 109–116.
2. Praetorius C, Sturm RA, Steingrimsson E. Sun-induced freckling: ephelides and solar lentigines. *Pigment Cell & Melanoma Research.* 2014; 27(3), 339–350. doi:10.1111/pcmr.12232
3. Zhang, X.J., He, P.P., Liang, Y.H., Yang, S., Yuan, W.T., Xu, S.J., and Huang, W. A gene for freckles maps to chromosome 4q32-q34. *J. Invest. Dermatol.* 2004; 122, 286–29
4. Nelson JS, Applebaum J. Treatment of superficial cutaneous pigmented lesions by melanin-specific selective photothermolysis using the Q-switched ruby laser. *Annals of Plastic Surgery.* 1992 Sep; 29 (3): 231-237. DOI: 10.1097/0000637-199209000-00007. PMID: 1524372.
5. Rümmelein B. Spectra XT: A Multiple Platform Nd:YAG Device. 2014; 54-55. <https://us.aesthetic.lutronic.com/assets/Uploads/media-files/SPECTRAXT-PRIME-Editorial-Sept2014.pdf>
6. RuVY Touch. *Lutronic Spectra XT Physician Clinical Guide*, 2-1 to 2-4.
7. Goo BL, Kang JS, Cho SB Therapeutic Efficacy and Safety of Wavelength-Converted 660-nm Q-Switched Ruby-Like Versatile YAG Treatment on Various Skin Pigmentation Disorders. *Med Laser.* 2014; 3(2): 48-54. <https://doi.org/10.25289/ML.2014.3.2.48>
8. Chan HH, Fung WK, Ying SY, Kono T. An in vivo trial comparing the use of different types of 532 nm Nd:YAG lasers in the treatment of facial lentigines in Oriental patients. *Dermatol Surg.* 2000; 26:743-9.
9. Anderson RR, Margolis RJ, Watanabe S, Flotte T, Hruza GJ, Dover JS. Selective photothermolysis of cutaneous pigmentation by Q-switched Nd: YAG laser pulses at 1064, 532, and 355 nm. *J Invest Dermatol.* 1989; 93:28-32.
10. Ho SG, Yeung CK, Chan NP, Shek SY, Chan HH. A comparison of Q-switched and long-pulsed alexandrite laser for the treatment of freckles and lentigines in oriental patients. *Lasers Surg Med.* 2011; 43:108-13.